

Ringworm Infection in Dogs and Cats (24-Jun-2003)

R. A. Cervantes Olivares

Departamento de Microbiología e Inmunología, Laboratorio de Micología, Facultad de Medicina Veterinaria y Zootecnia, Universidad Nacional Autónoma de México, México DF, México.

Introduction

Keratinophilic fungi are common inhabitants of the soil, where they process the hairs and skin cells shed by animals, as well as all types of keratin products that fall from animals and humans during the natural and continuous cycle of skin and coat shedding. The group of keratinophilic fungi is very large, but only three genera, known as dermatophytes, are known to cause disease ("ringworm") in animals and humans. The three genera involved are *Microsporum*, *Trichophyton* and *Epidermophyton*; the first two are most frequently found in animals while the third causes problems mainly in humans [1]. Ringworm is of importance not only because it can cause skin disease in dogs and cats, but it also can be transmitted to other animals as well as to humans. The particular ability of these three genera to be transmissible to animals, as well as to humans, signifies that they are an important, yet poorly understood, veterinary and human health problem worldwide [2]. A classification for dermatophytes based on their habitat was proposed in 1954 [3]. In a large survey of skin samples from animals and humans, dermatophytes were divided into three groups: **zoophylic** - those found mainly in animals, but transmitted to other animal or to humans; **anthropophylic** - those found mainly in humans and transmitted amongst humans, but very seldom to animals; and **geophylic** - dermatophytes found mainly in soil that infect both humans and animals.

This classification is still employed by many authors [4-6] because it helps to clarify the sources of a ringworm infection. Presently, it is known that virtually all dermatophytes are geophylic and that soil is the source of most infections [7].

Table 1. Dermatophytes isolated from dogs and cats with or without lesions

	Year	Author	City/Country	No. Cat Samples	No. Dog Samples	% Cat Positive	% Dog Positive
Animals without Lesions	1987	Piontelli [17]	Valparaiso/Chile	87	191	30.9	23.03
	1988	Zaror [18]	Valdivia/Chile	56	130	30.4	18.4
	1988	Ali-Sthayeh [19]	Israel	23	11	21.7	9.09
	1989	Caretta [20]	Pavia/Italy	93	168	75	36.9
	1989	Bernardo [21]	Lisboa/Portugal	92	666	29.3	21.3
	1992	Wawrkiewicz [22]	Lublin/Poland	85	99	31.7	0
Animals with Lesions	1990	Lewis [1]	Louisiana/USA	408	1824	14.9	3.8
	1991	Vokoun [23]	Prague/Czechoslovakia	112	836	19	18
	1993	Katoh [24]	Tokyo/Japan	20	7	100	42
	1993	Sparkes [25]	Bristol/UK	3407	4942	26	10
	1995	Marchisio [6]	Torino/Italia	105	98	50.5	29.6

Dogs and cats can suffer a dermatophyte infection at any age, but ringworm infections in the young are most frequent [8,9]. In addition to age, risk factors include poor nutrition, high density of animals, poor management and lack of an adequate quarantine period for infected pets.

It is important to note that canine and feline ringworm infections differ clinically. Canine infections generally produce lesions, whereas clinical signs may not be evident in cats. In cats, it is possible to culture dermatophytes from clinically healthy animals that act only as carriers of conidia, without being infected [10,11].

The literature on companion animal dermatophytoses records great differences between canine and feline ringworm infections [12-14]. For example, some reports are based on samples taken only from animals showing ringworm lesions; others reveal different results with samples taken randomly from animals in the population with no lesions. Although a very low rate of dermatophyte recovery has been recorded population-wide, higher rates are found in cats than in dogs [14-16]. Table 1 lists results from a series of reports that reveal the great variation in the number of positive ringworm recoveries from dogs and cats in different parts of the world and from different clinical backgrounds.

The most common fungus isolated from dog and cat fur is *Microsporum canis*, followed by *M. gypseum* and *Trichophyton mentagrophytes*. Those three genera are the so-called zoophylic strains and they are the most reported dermatophytes found worldwide [17-19].

Clinical features [20-26]

Typical ringworm lesions are round with embossed edges; they appear as patches on the skin giving the impression of the hair having been shaved. Lesions can occur in any part of the body, but they occur mainly in the head, ears, tail and front paws. Dermatophytes must invade the *stratum corneum* of the skin and/or the hair. Once the fungus has entered the *stratum corneum*, hair follicles are readily invaded. The organisms grow downward on the hair surface using keratolytic enzymes that allow hyphae to penetrate the hair cuticle until they reach a critical level, the "fringe of Adamson". Dermatophytes only invade hairs that are growing; hairs in a resting stage are not invaded since essential nutrients for fungal growth are absent or limited.

Lesions are more conspicuous in young animals, while older ones have discrete lesions, or none at all. In many cases alopecia is present in the infected lesions, but this sign may be absent, especially in cats.

Canine ringworm lesions often appear as circular, bald patches 1 to 4 cm in diameter. The hair is broken at the base in lesion areas, creating a shaved appearance. Pale skin scales usually occupy the center of the lesion and have a "powdery" appearance, while the edges form an erythematous ring. If individual lesions coalesce, an irregular, large lesion configuration can be observed (Fig.1).



Figure 1. Ringworm caused by *Microsporum canis*. Individual lesions may coalesce, resulting in large, irregular lesion configurations. - To view this image in full size go to the IVIS website at www.ivis.org . -

At the beginning of the infection vesicles and pustules may be observed; later, a crust commonly covers the lesion which has swollen edges. In dogs, The differential diagnoses include folliculitis, furunculosis, alopecia, demodicosis, or immune-mediated skin diseases. Concurrent mite infestations or bacterial infections may occur that can cause focal hyperpigmentation. In cats, miliary dermatitis and several other skin infections may mimic ringworm. Over 98% of ringworm infections of cats are caused by *Microsporum canis*.

Methods for the diagnosis of ringworm in dogs and cats [25-29]

Wood's lamp emits UV light at a wavelength of 330 - 365 nm and is used in a dark room to examine hairs for certain dermatophytes by shining the light directly on the sample. *Microsporum canis* and *M. equinum* show a yellowish-green fluorescence due to the pteridine secreted by these fungi.



Figure 2. Fluorescent hair of a dog infected with *Microsporum canis*. Wood's lamp. (With permission from Veterinary Bacteriology and Mycology, School of Veterinary Medicine, University of Wisconsin, USA). - To view this image in full size go to the IVIS website at www.ivis.org . -

The use of a Wood's lamp is a useful tool in the small animal clinic, but it has limitations since not all *M. canis* strains show

fluorescence; some topical preparations mask the fluorescence. Also, if the skin is swabbed with alcohol the fluorescence may be less intense and there may be a non-specific fluorescence. When using Wood's lamp, a bright green fluorescence can be taken as an indication of dermatophytosis, but its absence is not sufficient evidence to rule out this condition since the dermatophytosis present may be due to fungal species that produces little or no fluorescence (Fig.2).

Methods for sampling suspected ringworm infected dogs and cats

Skin scrapings or use of plucked hair are the most common methods used worldwide. The method is simple if the animal is properly restrained, but it can be difficult in some cases, especially with adult cats. The skin sample skin should be taken from the edge of the lesion with a surgical blade. Scrapings should be taken very superficially to avoid bleeding. Samples should be collected on a paper envelope or a black piece of paper - it is easier to see the skin scrapings in a dark background - and some hairs must be taken by plucking them off with forceps. There is no value in cutting the hairs because the fungal parasitic structures (arthroconidia) are in the base of the hair.

Alternatively Mackenzie's technique [26] may be used (Fig. 3). It consists of brushing the fur of an animal with a disinfected dental brush and is probably the best option if required to sample large numbers of infected animals or where it is difficult to restrain them, e.g., adult cats.



Figure 3. Mackenzie's technique consists of brushing an animal's fur with a disinfected dental brush, followed by culture in an appropriate medium. - To view this image in full size go to the IVIS website at www.ivis.org . -

Direct Microscopic Examination

The parasitic form of dermatophytes in animal tissues appears as slender, greenish filaments in skin scrapings or so-called arthroconidia inside or around the hair, creating a sheet of spores [28,29].

In order to visualize those structures it is necessary to clear the sample using a strong alkali solution such as KOH, NaOH or Ca(OH)₂; 10% KOH is the most common solution used by mycologists and clinicians (Fig.4 and Fig.5).



Figure 4. Sheet of arthroconidia (arrow) revealed after treatment of a skin scraping with 10% KOH. This diagnostic method for ringworm is commonly used by both mycologists and clinicians. - To view this image in full size go to the IVIS website at www.ivis.org . -




Figure 5. Fungal hyphae (arrows) in skin scraping treated with 10% KOH. - To view this image in full size go to the IVIS website at www.ivis.org . -

A different technique is used to visualize dermatophyte structures. The method uses a potassium hydroxide-calcofluor white (CFW) mixture. CFW binds to the chitin in the fungal cell wall and fluoresces bright green to blue under ultraviolet light, using a fluorescence microscope. A substantial amount of non-specific fluorescence from animal cell materials, as well as natural and synthetic fibers, may be expected with this technique. CFW highlights suspicious structures; however, the interpretation of structures relies on the recognition of traditional fungal morphologic features [29].

Culture

The fur of animals is generally highly contaminated, especially by fungal conidia, spores and bacteria. Patience is required to obtain an isolate of the slow-growing dermatophytes and it is necessary to use media that help to prevent overgrowth of saprophytic fungi or bacteria. Mycologists often have their own recipe for culturing dermatophytes, but several commercial media are available that include the basic ingredients. These include 4% glucose, 1% peptone, 2% agar (Sabouraud's dextrose agar, SDA) together with antibacterial agents such as , or a combination of penicillin, streptomycin and cycloheximide - a substance that helps to slow the growth of fast growing fungi. The genera of dermatophytes that have been reported in dogs and cats will grow in about 4 to 7 days at 25 - 28°C (Fig. 6).

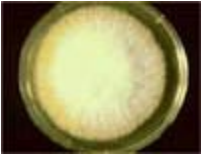

Figure 6. *M. canis* culture. Growth of dermatophytes (Microsporum and Trichophyton) is optimal at 25 - 28°C, with luxuriant growth in about 4 to 7 days. - To view this image in full size go to the IVIS website at www.ivis.org . -

Dermatophyte Test Media (DTM)

The use of DTM is very helpful in confirming the isolation of a dermatophyte. DTM is commercially available and can be easily obtained by clinicians that commonly use it to aid in the initial diagnosis of ringworm. DTM has a pH indicator (phenol red) which changes the initial amber medium to red when a dermatophyte is growing. Unfortunately, there are many different fungi as well as bacteria, that can grow in DTM and produce a pH change. A mycological study is the only way to confirm the nature of the growth [7].

Identification and Characterization of Dermatophytes

After the primary isolation of a suspected dermatophyte, it is necessary to identify the genus and species. The traditional method is to make a "slide culture". Although there are several modifications of this technique, the easiest one was described by Harris [29]. The components of the system consist of a Petri dish, a "V-shaped" glass rod, a slide and a cover slip, all which are sterilized by autoclaving. The system is prepared by placing the slide on top of the glass rod support. A small square block (1 cm²) is cut from a plate of SDA with a sterile spatula or scalpel and then transferred to the center of the slide. The solid medium is then inoculated by placing a small amount of a suspected dermatophyte on the 4 sides of the block with a cover slip placed on the top. A mixture of glycerin-water should be added to the bottom of the Petri dish in order to prevent dehydration of the medium.

After inoculation, the Petri dish is closed and incubated at 25 - 28°C. Fungal growth can be observed at the point of inoculation and it may eventually cover the surface of the slide as well as the undersurface of the cover slip. The reproductive structures (macroconidia, microconidia, spiral hyphae, etc) are helpful in identifying the fungus type. To harvest the slide culture, it is necessary to have a clean slide and cover slip ready to make observations, using a drop of Lactophenol Cotton Blue (LPCB). Carefully lift the cover slip with forceps from the fully-grown slide culture and mount the cover slip on a clean slide using a drop of LPCB. Avoid bubbles, as they have a way of becoming trapped in the most interesting and critical parts of the preparation, deforming the visual path and obstructing a clear view of the conidia. Lift the remainder of the slide culture out of the Petri dish, expel the agar block into disinfectant solution and detach it as neatly as possible, taking care not to push it across the slide and ruin the preparation. Put a small drop of LPCB on the slide and mount on a clean coverslip. Finally, examine the slides under low and medium magnification. The use of an identification manual is necessary to fully characterize the genus and species of a fungus. Two commonly used manuals are those of Rebell and Taplin [7] and Mackenzie and Philpot [15].

Microsporum canis - A flat, white, fluffy, spreading colony develops within 7 to 14 days. A characteristic deep yellow pigment may be observed on the reverse side of a colony on Sabouraud dextrose agar or DTM. On DTM, the media should change from amber to red, concurrent with growth. Observation of a LPCB mount will reveal septate hyphae and numerous, fusiform, thick-walled macroconidia that usually contain more than six compartments. A few club-shaped, smooth-walled microconidia also may be present, as well as round-shaped clamidoconidia [26] (Fig.7 and Fig.8).



Figure 7. *Microsporum canis*, showing septate hyphae and numerous, fusiform, thick-walled macroconidia (arrow) that usually contain more than 6 septa. - To view this image in full size go to the IVIS website at www.ivis.org . -

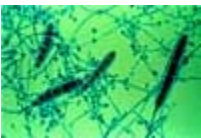

Figure 8. Macroconidia and microconidia of *Microsporum canis*. (With permission from Veterinary Bacteriology and Mycology, School of Veterinary Medicine, University of Wisconsin, USA). - To view this image in full size go to the IVIS website at www.ivis.org . -

Microsporum gypseum - A flat, cinnamon to buff-colored colony with a powdery surface develops within 7 to 14 days on Sabouraud dextrose agar or DTM. On DTM, the media should change from amber to red concurrent with growth. Observation of a LPCB mount will reveal septate hyphae and numerous thin-walled, elliptical macroconidia that usually contain no more than six compartments. A few smooth-walled, club-shaped microconidia may be present (Fig. 9a).



Figure 9a. *M. gypseum*. (With permission from Veterinary Bacteriology and Mycology, School of Veterinary Medicine, University of Wisconsin, USA). Observation of a LPCB mount will reveal septate hyphae and numerous thin-walled, elliptical macroconidia that usually contain no more than six compartments. A few smooth-walled, club-shaped microconidia may be present. - To view this image in full size go to the IVIS website at www.ivis.org . -

Trichophyton mentagrophytes - On Sabouraud dextrose agar or DTM, a colony with a powdery or cottony surface, which is usually flatter than that of *M. canis*, develops within 7 to 14 days (Fig. 9b and Fig. 9c). The reverse side is usually brown. On DTM, the media should change from amber to red concurrent with growth. Observation of a LPCB mount will reveal septate hyphae. Numerous round microconidia are present in clusters on the conidiophores. Spiral coils are often observed. Cigar-shaped macroconidia may be present in some cultures.



Figure 9b. *Trichophyton mentagrophytes* colony with a powdery or cottony surface on Sabouraud dextrose agar. - To view this image in full size go to the IVIS website at www.ivis.org . -



Figure 9c. *Trichophyton Mentagrophytes* - "Downy" surface on phytone yeast extract (PYE) agar. - To view this image in full size go to the IVIS website at www.ivis.org . -

Prophylaxis

It is well known that keratinophilic fungi require keratin to survive; it is therefore advisable to remove from animal quarters as much material as possible that contains keratin. It is commonly believed that fungal spores are highly resistant to disinfectants but this belief is erroneous. Dermatophyte spores are susceptible to several common disinfectants such as benzalkonium chloride, dilute (1:10) chlorine bleach, or strong detergents. Mechanical removal (e.g., vacuum cleaner with filter) of hair and skin cells, from areas where infected animals had been, followed by disinfection, will help to control the spread of ringworm infections [30]. Chlorhexidine has not been found to be effective as an environmental decontaminant. Corticosteroid drugs are contraindicated.

Effective therapy is based on elimination of the infection on an animal, prevention of further dissemination and removal of infective materials in the environment. Prevention in kennels or households where dermatophytes have been a problem also involves initiating a quarantine period and culturing all animals entering a kennel or household to prevent reinfection. Infective soil should be avoided, especially if a geophyllic dermatophyte is involved. Some veterinarians advocate using griseofulvin for 1-2 weeks as prophylactic treatment of exposed animals (see comments below).

Treatment

Treatment of infected pets can be both expensive and very frustrating, especially in households or kennels where several animals are kept. It is difficult to recommend a universal treatment for ringworm in dogs and cats - the clinician must consider whether an infected animal is likely to respond to local treatment with an antifungal cream, or whether systemic therapy with griseofulvin, ketoconazole, or other systemic drugs is required.

Generally, topical treatment fails because dogs and cats usually remove the drug by licking. Also, topical treatment alone does not hasten recovery and it is no longer recommended as the sole treatment, but it may have some value in limiting spread of the organisms to the environment [31]. Lime sulfur (2 - 2.5% sulfur solution), enilconazole (not available in the USA) and miconazole shampoos are considered the most effective topical agents, but signs may be exacerbated after initial treatment and results are variable.

Systemic drugs include griseofulvin, ketoconazole, itraconazole and fluconazole. It should be noted that griseofulvin may cause bone marrow suppression, with anaemia and pancytopenia, thus weekly or biweekly complete blood counts are recommended. Neutropenia is the most common cause of death in cats. Griseofulvin should not be used during the first two thirds of pregnancy, as it is teratogenic. Ketoconazole may cause liver pathology and inhibits the production of steroid

hormones in dogs and should not be used as a first line antifungal, but reserved for resistant cases. Many clinicians now prefer itraconazole to ketoconazole because of fewer side effects and similar, or greater efficacy. However, itraconazole is very expensive. It is a triazole drug that is absorbed rapidly when taken with food. It is better tolerated than ketoconazole and has less effect on liver function. It is preferred in cats over ketoconazole. Reference 31 should be consulted for further discussion of therapy. Repeated fungal cultures at the end of a treatment regimen should be done, with continued treatment until cultures are negative.

The prognosis depends on the extent of the infection and success in treatment. Often, animals will "self clear" after several months, but treatment helps to accelerate recovery and reduce environmental contamination. Long-haired cats appear to suffer more persistent infections; treatment is especially difficult where there are several animals housed together.

Although several excellent reviews are available on canine and feline dermatophytosis [31-34], the problems of ringworm infections are still largely unresolved in veterinary medicine and more effective treatments are needed.

References

1. Lewis DT, Foil CS, Hosgood G. Epidemiology and Clinical Features of Dermatophytosis in Dogs and Cats at Louisiana State University:1981-1990. *Vet Dermatol* 1991; 2:53-58.
2. Chretien JH, Garagusi VF. Infections Associated with Pets. *Am Fam Physician* 1990; 41:831-845.
3. Georg LK. Animal Ringworm in Public Health. Dermatophytes: New methods in classification. Atlanta, GA, US. Public Health Service, 1954.
4. Medleau L, White-Welther NE. Dermatophytosis in Cats. *Compend Contin Educ Prac Vet* 1991; 13:557-562.
5. Moriello KA, DeBoer DJ. Fungal flora of the coat of pet cats. *Am J Vet Res* 1991; 52:602-606.
6. Marchisio VF, Gallo MG, Tullio V, et al. Dermatophytes from cases of skin disease in cats and dogs in Turin, Italy. *Mycoses* 1995; 38:239-244.
7. Rebell G, Taplin, D. Dermatophytes: Their recognition and identification. Miami,: University of Miami Press. 1974.
8. Wright AI. Ringworm in dogs and cats. *J Small Anim Pract* 1989; 30:242-249.
9. Pier AC, Moriello KA. Parasitic relationship between *Microsporum canis* and the cat. *Med Mycol* 1998; 36:271-275.
10. Sparkes AH, Werret G, Stokes CR, Gruffydd-Jones TJ. *Microsporum canis*: Innaparent carriage by cats and the viability of arthrospores. *J Small Anim Pract* 1994; 35:397-401.
11. Thomas MLE, Scheidt VJ, Walker RL. Inapparent carriage of *Microsporum canis* in cats. *Compend Contin Educ Prac Vet* 1989; 11:563-570.
12. Dvorak J, Otcenasek M. Mycological Diagnosis of Animal Dermatophytoses, Prague: Academy of Sciences 1969.
13. Fernández GJR. Dermatofitosis felinas. Consideraciones zoonóticas., *Med Vet* 1995: 12:361-371.
14. Moriello KA, Kunlke G, DeBoer DJ: Isolation of dermatophytes from the haircoats of stray cats from selected animal shelters in two different geographic regions in the United States. *Vet Dermatol* 1994; 5:57-62.
15. Mackenzie DWR, Philpot CM. Isolation and identification of ringworm fungi. Public Health Laboratory Service. Monograph Series No 15. HM Stationary Office London, UK, 1981.
16. Guzman-Chavez RE, Segundo-Zaragoza C, Cervantes-Olivares RA, et al. Presence of keratinophilic fungi with special reference to dermatophytes on the haircoat of dogs and cats in Mexico and Nezahualcoyotl cities. *Rev Latinoam Microbiol* 2000; 42:41-44.

17. Piontelli L, Toro MA. Los animales domésticos (perros y gatos) como reservorio fúngico. *Bol Micol* 1987; 4:149-158.
18. Zaror L, Casas S. Dermatophytes in healthy dogs and cats in Valdivia, Chile. *Arch Med Vet Chile* 1988; 20:140-143.
19. Ali-Shtayeh MS, Arda HM, Hassouna M, et al. Keratinophilic fungi on the hair of cows, donkeys, rabbits, cats, and dogs from the West Bank of Jordan. *Mycopathol* 1988; 104:109-21.
20. Caretta G, Manciante F, Ajello L. Dermatophytes and keratinophilic fungi in cats and dogs. *Mycoses* 1989; 32:620-626.
21. Bernardo FM, Martins HM, Mendes AM. Survey of dermatophytes in companion animals in Portugal. *Rep Trab LNIIV* 1989; 21:83-88.
22. Wawrzkievicz K, Ziolkowska G, Czajkowska A. *Microsporum canis* in clinically healthy cats and dogs. *Med Wet* 1992; 48:546-548.
23. Vokoun P, Kucera K. Study of dermatomycoses of dogs and cats in an urban area. *Veterinarstvi* 1991; 41:250-254.
24. Katoh T, Nishioka K, Sano T. A mycological study of pets as the source of human infection due to *Microsporum canis*. *Jap J Med Mycol* 1993; 34:325-330.
25. Sparkes AH, Gruffydd-Jones TJ. Epidemiological and diagnostic features of canine and feline dermatophytosis in the United Kingdom from 1956 to 1991. *Vet Rec* 1993; 133:57-61.
26. Mackenzie DWR. "Hairbrush Diagnosis" in detection and eradication of non-florescent scalp ringworm. *Brit Med J* 1963; 2:363-365.
27. Medleau, L, Ristic Z. Diagnosing dermatophytosis in dogs and cats. *Vet Med* 1992; 87:1086-1092.
28. Hendrikson DA, Krenz MM. Reagents and stains, In: Balows et al., (eds). *Manual of Clinical Microbiology*, 5th ed. Washington DC: American Society for Microbiology, 1991; 1303.
29. Harris JL. Modified method for fungal slide culture. *J Clin Microbiol* 1986; 24:460-461.
30. Rycroft AN, McLay C. Disinfectants in the control of small animal ringworm due to *Microsporum canis*. *Vet Rec* 1991; 129:239-241
31. Moriello KA, DeBoer DJ. Feline dermatophytosis. Recent advances and recommendations for therapy. *Vet Clin North Am Small Anim Pract* 1995; 25:901-921
32. Ainsworth GC, Auswick PK. *Fungal Diseases of Animals*, 2nd edition, Review Series No. 6 of the Commonwealth Bureau of Animal Health, Kew, Surrey, UK 1973.
33. Kane J, Summerbell R, Sigler L, et al. *Laboratory Handbook of Dermatophytes*. Belmont: Star Publishing Company 1997.
34. Van Cutsem J, Rochette F. *Mycoses in domestic animals*. Janssen Research Foundation 1991.

All rights reserved. This document is available on-line at www.ivis.org. Document No. A0113.0603.

