

Ulcers in the Stomach and Colon; Diagnosis and Treatment: A Pain in the Gut!

Frank M. Andrews, DVM, MS

Author's Address: Professor and Section Chief, Large Animal Medicine, Department of Large Animal Clinical Sciences, The University of Tennessee, College of Veterinary Medicine, Knoxville, Tennessee 37996. fandrews@utk.edu.

Take Home Message

Equine Gastric Ulcer Syndrome (EGUS) and Right Dorsal Colitis (RDC) are common in performance horses. Diagnoses are based on history, clinical signs, laboratory findings, gastroscopic examination, and response to altered diet and medical therapy. Effective treatment strategies for EGUS focus on increasing stomach pH by inhibiting or buffering gastric acid, which allows a permissive environment for ulcer healing, and environmental and dietary management. Effective treatment strategies for RDC focus on removing non-steroidal anti-inflammatory drugs (NSAIDs), decreasing the bulk in the diet, reducing inflammation, coating and lubricating the colon and decreasing environmental stress. Prevention of these conditions requires long-term dietary and environmental management.

Equine Gastric Ulcer Syndrome

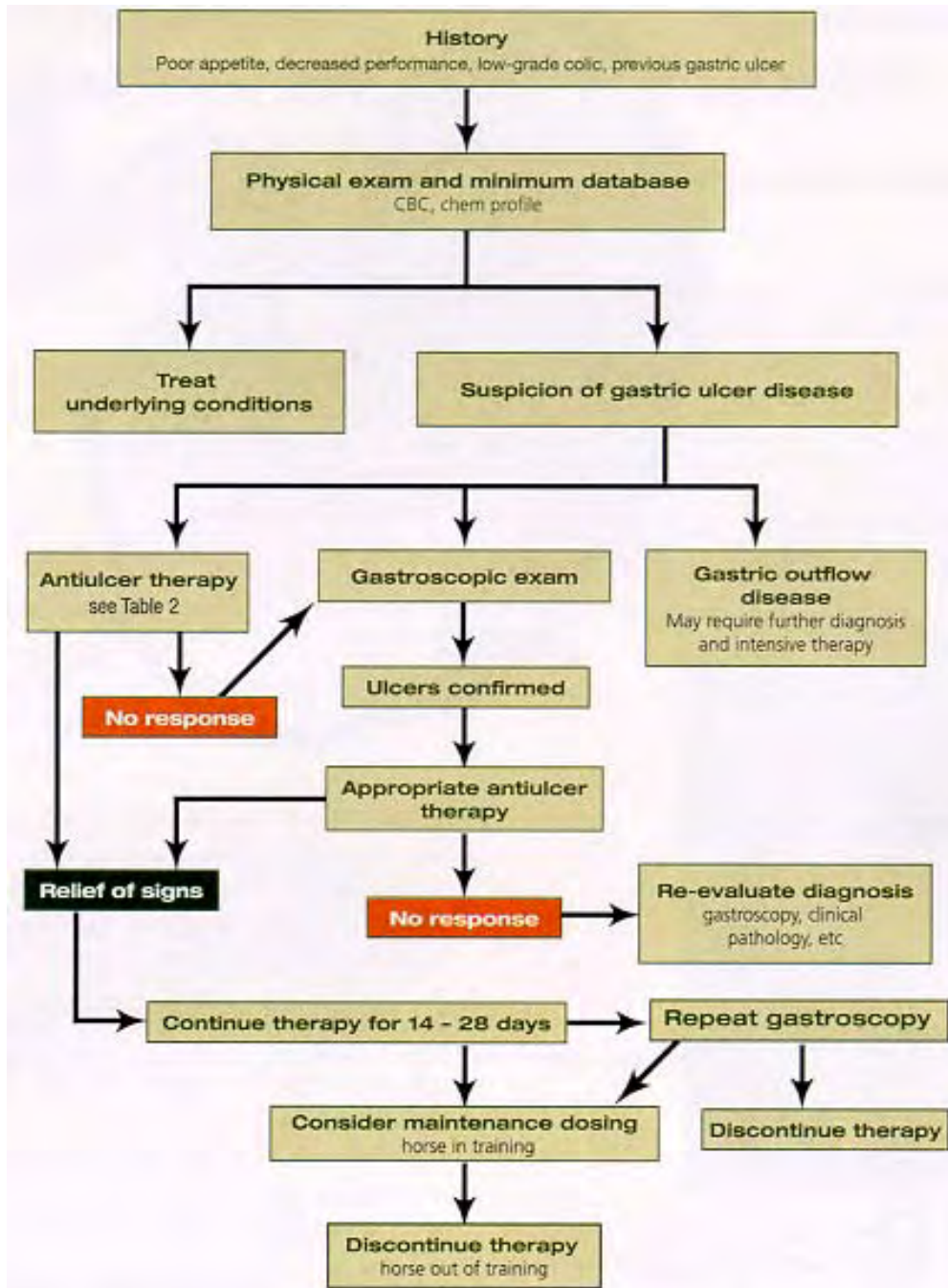
Gastric ulcers are common in performance horses. The term Equine Gastric Ulcer Syndrome (EGUS) was coined to describe the condition of erosions and ulcerations occurring in the distal esophagus, non-glandular and glandular stomach, and proximal duodenum of horses.¹ EGUS is caused by many factors including anatomy of the stomach, exercise, restricted feed intake, diet, environmental stress (stall or transport), and the use of non-steroidal anti-inflammatory agents.² Diagnosis of EGUS is based on history, clinical signs, endoscopic examination, and response to treatment. All ages and breeds of horses are susceptible to EGUS and current therapeutic strategies focus on blocking gastric acid secretion and raising stomach pH to ≥ 4.0 . To date there is only one Federal Drug Administration (FDA) approved pharmacologic agent for treatment of EGUS; GastroGard® (Merial Limited, Duluth, GA). However, a more comprehensive approach to EGUS diagnosis and treatment includes determining and correcting of the underlying cause, environmental management, dietary manipulation, and pharmacologic intervention.

Diagnosis

The approach to diagnosis of EGUS requires a thorough history, physical examination, and a minimum database (Figure 1). Identifying risk factors and clinical signs are helpful in diagnosing EGUS (Table 1). However, gastroscopy is the only definitive diagnosis of EGUS currently available. The procedure for gastroscopy has been described in detail elsewhere, but requires at least a 2 meter endoscope to visualize the non-glandular mucosa and margo plicatus and a 2.5m to 3m endoscope to visualize the pyloric antrum

and proximal duodenum in most adult horses. Once visualized, ulcers should be scored using a scoring system developed for horses.¹ Use of a scoring system allows the clinician to compare gastroscopic findings and monitoring healing of ulcer to evaluate efficacy of treatment.

Figure 1. Diagnosis and Treatment of EGUS



Reproduced from Andrews F, Bernard W, Byars D, Cohen N, Divers T, MacAllister C, et al. Recommendations for the diagnosis and treatment of equine gastric ulcer syndrome (EGUS). *Equine Vet Educ* 1999; 1 (2): 122-134.

Currently there are no hematologic or biochemical markers to diagnose EGUS. Some horses with EGUS may be slightly anemic or hypoproteinemia, but this is rare. However, O'Connor et al.³ recently evaluated the potential of a sucrose permeability test to diagnose gastric ulcers. Urine sucrose concentrations were significantly higher for horses with gastric ulcer scores > 1. Using a urine sucrose concentration cutoff value of 0.7 mg/ml or higher revealed an apparent sensitivity of 83% and specificity of 90% to detect ulcers in horses tested using the sucrose permeability test. Thus, this test may provide a simple, noninvasive test to detect and monitor gastric ulcers.

Because of the lack of any additional laboratory diagnosis, in situations where ulcers are strongly suspected, but gastroscopy is not available, it may be worthwhile to start empirical treatment and observe for resolution of clinical signs. If the horse does not respond to treatment within several days, referral to a facility for gastroscopic examination is indicated.

Table 1. Clinical Signs and Risk Factors of EGUS.

<u>Clinical Signs Adults</u>	<u>Foals</u>	<u>Risk Factors</u>
Acute colic	Diarrhea	Stress
Recurring colic	Abdominal pain	Transportation
Excessive recumbency	Restlessness	High-grain diet
Poor body condition	Rolling	Stall confinement
Partial anorexia	Lying in dorsal recumbency	Intermittent feeding
Poor appetite	Excessive salivation	Intense exercise
Poor performance/training	Bruxism	Racing
Attitude changes	Intermittent nursing	Illness
Stretching often to urinate	Poor appetite	NSAID use
Inadequate energy		Management changes
Chronic diarrhea		

Treatment

The goals of EGUS therapy are to relieve pain, eliminate clinical signs, promote healing, prevent secondary complications, and prevent recurrence. The mainstay of EGUS treatment is to increase stomach pH by suppressing stomach HCl acid secretion. Pharmacologic therapy is popular and several agents have proven helpful in EGUS treatment, but the only FDA approved drug for treatment and prevention of recurrence of gastric ulcers in horses is GastroGard® (Table 2). Because of the high recurrence rate, effective acid control should be followed by altered management strategies and/or long-term treatment to prevent ulcer recurrence. Recently, UlcerGard® (Merial LTD, Duluth, GA), a low dose omeprazole paste, was approved as a non-prescription medication for prevention of gastric ulcers in horses (Table 2). Many feed additives and nutraceutical agents are available that claim efficacy, but to the authors' knowledge, there are no published scientific data on the efficacy of these compound in the treatment or prevention

of EGUS. Also, compounded formulations of omeprazole lack the stringent efficacy and safety studies that are required for FDA approval and have little chance of efficacy. Also, the chemical properties of omeprazole make it difficult to compound while maintaining efficacy and potency. Many compounded forms of omeprazole are inactivated in the bottle prior to administration and two recent studies confirmed that compounded omeprazole suspensions were ineffective in healing gastric ulcers in racehorses in training.^{4,5}

Table 2. Drug Therapy for Treatment of EGUS.

Drug	Dosage	Dosing Interval	Route of Administration
Omeprazole	0.5 mg/kg	Intravenously	Q 24 hrs
Omeprazole (GastroGard™)	4 mg/kg (Treatment of Ulcers)	Orally	Q 24 hrs
Omeprazole (GastroGard™)	2 mg/kg (Prevention of Recurrence)		
Omeprazole (UlcerGard™)	1 mg/kg (Prevention of Ulcers)	Orally	Q 24 hrs
Ranitidine	1.5 mg/kg	Intravenously	Q 6 hrs
Ranitidine	6.6 mg/kg	Orally	Q 8 hrs
Misoprostol	5 mcg/kg	Orally	Q 8 hrs
Sucralfate	20-40 mg/kg	Orally	Q 8 hrs
AlOH/MgOH antacids	30g AlOH/15 g MgOH	Orally	Q 2hrs
Bethanecol	0.025 – 0.30 mg/kg	Subcutaneous	Q 3-4 hrs
Bethanecol	0.3-0.45 mg/kg	Orally	Q 6-8 hrs

Antibiotics (Helicobacter spp.)

Helicobacter has not been cultured from the horse stomach, but DNA from a *Helicobacter-like* bacteria was found in the stomach mucosa of horses using a Polymer Chain Reaction test (PCR).⁶ Although *Helicobacter* has not been cultured from horses there are some horses that do not respond to conventional antiulcer therapy. In this group of horses with chronic non-responsive EGUS, we recommend combination therapy

consisting of omeprazole (4 mg/kg, orally, q24hr), metronidazole (15 mg/kg, orally, q6-8hrs) and/or trimethoprim/sulfa (15 to 25 mg/kg, orally, q12hrs), and bismuth subsalicylate (3.8 mg/kg, orally, q6hrs). An initial 14-day treatment period is prescribed, which should be followed by gastroscopy. Some horses may require longer treatment. Omeprazole therapy should be continued for the full 28 days if needed.

Dietary Management

In conjunction with pharmacological therapy, environmental and dietary management may be helpful to facilitate ulcer healing. Limited fasting periods, limited feeding of high soluble carbohydrate diets and providing good quality alfalfa or grass hay *ad lib* can help buffer stomach contents and reduce gastric acidity. Also, pasture turnout (when possible) can help reduce stress and control formation of gastric ulcers.

Right Dorsal Colitis (Colonic Ulcers)

Unlike EGUS, colonic ulcers and the condition Right Dorsal Colitis (RDC) occur less frequently, but may lead to hypoproteinemia and more severe clinical signs. In a necroscopic study of 545 horses, 44% of non-performance horses and 65% of the performance horses had colonic ulcers.⁷ Colonic ulcers are probably associated with inhibition of prostaglandins by stress induced release of endogenous corticosteroids or the administration of NSAIDs. Early in the condition, horses present with non-specific signs of mild intermittent or recurring colic episodes, lethargy and partial anorexia. However, as the condition worsens clinical signs may include complete anorexia, fever, and diarrhea. Progression of RDC may lead to dehydration, ventral edema, and weight loss. Differential diagnoses for this condition include EGUS, large colon displacement and/or impaction, infectious causes of diarrhea (Salmonellosis, Potomac Horse Fever, Clostridium), granulomatous enteritis, eosinophilic enterocolitis, and intestinal neoplasia.

Diagnosis

A presumptive diagnosis of RDC can be made on history, clinical signs, changes on CBC (mild anemia, toxic changes in PMNs, left shift), hyperfibrinogenemia, hypoalbuminemia, and hypocalcemia. Peritoneal fluid analysis may show a mild increase in WBC count and increase in total protein concentration. In a recent study, a guaiac-based fecal occult blood test was shown to have a good positive predictive value (72%) and a poor negative predictive value (51%) in the diagnosis of RDC.⁷ In that study many horses that had gastric or colonic ulcers had negative tests (i.e. false negatives). Gastroscopic examination of the stomach if negative may help rule-in RDC in horses showing typical clinical signs, especially if there is concurrent hypoproteinemia. Abdominal ultrasonography of the right dorsal colon may show mural thickening (normal = < 4mm).⁸ The peripheral wall of the right dorsal colon can be scanned percutaneously through intercostals spaces 11 to 15, ventral to the ventral margin of the right lung field.⁸

Every effort should be made to rule-out infectious causes of diarrhea such as, Salmonellosis and Potomac Horse fever (PHF) in horses with diarrhea. Fecal cultures and PHF serology and PCR can be helpful in ruling-out these conditions. Horses with Salmonellosis will have signs similar to RDC and these diseases may occur together.

Treatment

The principle goals of treatment for RDC includes discontinuing use of NSAIDs, decreasing gut fill to allow the colon to rest, frequent feedings, reducing inflammation, and restoring the normal colon absorptive function. Reduction in gut fill can be accomplished by decreasing or eliminating dry hay from the diet and replacing with frequent feeding of alfalfa-based pelleted complete feeds with at least 30% dietary fiber (Purina Senior™, Purina Mills, St. Louis, MO). This reduces gut fill and decreases the mechanical load on the colon. The horse can be allowed to graze small amounts of fresh grass (10 to 15 minute intervals four to six times daily) to help maintain body weight. The switch to a complete feed diet should be made over several days to a week to allow the gastrointestinal tract time to acclimatize to the feed change. The complete feed diet should be continued for 3 to 4 months or at which time hypoproteinemia and hypoalbuminemia has resolved.

Psyllium mucilloid (Equisyl Advantage™, Animal Health Care Products) or psyllium hydrophilic mucilloid (Metamucil®, Proctor & Gamble, Cincinnati, OH) can be added to the diet to shorten transit time for ingesta and increase water content of the GI tract. Also, psyllium increase the concentration of short-chain fatty acids in the colon of other species which reduces inflammation and thus may reduce inflammation in the horse colon. Furthermore, Corn or Safflower oil (1 cup, added to feed, q12h) can be added to the complete feed to increase Omega-3 fatty acids. Omega-3 fatty acids competitively inhibit the activity of cyclooxygenase enzyme, which is necessary for eicosanoid production. A diet rich in omega-3 fatty acids may reduce the eicosanoid production, thereby decreasing inflammation.

The use of medication routinely used for gastric ulcers (antacids, omeprazole, or ranitidine) would not be expected to be effective in treatment of RDC. However, sucralfate (22 mg/kg, orally, q6-8h), a sucrose octasulfate and polyaluminum hydroxide complex, has been used for treatment of RDC. This compound has a strong affinity to bind to gastrointestinal mucosa. It has a greater affinity to bind to ulcer craters when compared to intact epithelial cells. In man, sucralfate is more adherent to duodenal ulcers than gastric ulcers despite the duodenal pH > 4.0.⁹ Thus, sucralfate may bind to “ulcer craters” in the colon of horses forming a proteinaceous bandage. Furthermore, sucralfate, once bound to the ulcer crater, may stimulate local prostaglandin production which may exert a “cytoprotective” effect on the colon mucosa.

Minimizing physiologic and environmental stresses can also be helpful in controlling RDC. Stall rest, reduction of strenuous exercise or training, and reduction in transport are ways to decrease stress. Horses should always have adequate amounts of clean fresh water and should be provided a mineral/salt mix to ensure adequate water intake.⁸

References

1. Andrews F, Bernard W, Byars D, Cohen N, Divers T, MacAllister C, et al. Recommendations for the diagnosis and treatment of equine gastric ulcer syndrome (EGUS). *Equine Vet Educ* 1999; 1 (2): 122-134.

2. Buchanan BR, Andrews FM. Treatment and prevention of equine gastric ulcer syndrome. *Vet Clin North Am Equine Pract* 2002;19:575-579.
3. O'Connor MS, Steiner JM, Roussel AJ, et al. Evaluation of urine sucrose concentration for detection of gastric ulcers in horses. *Am J Vet Res* 2004;65:31-39.
4. Orsini JA, Haddock M, Stine L, et al. Odds of moderate or severe gastric ulceration in racehorses receiving antiulcer medications. *J Am Vet Med Assoc* 2003;223:336-339.
5. Nieto JE, Spier S, Pipers FS, et al. Comparison of paste and suspension formulations of omeprazole in the healing of gastric ulcers in racehorses in active training. *J Am Vet Med Assoc* 2002;221:1139-1143.
6. Scott DR, Marcus EA, Shirazi-Beechey SSP, et al. Evidence of *Helicobacter* infection in the horse. In *Proceedings*. Am Soc Microbiologists 2001:287.
7. Pellegrini FL. Results of a large-scale necroscopic study of equine colonic ulcers. *J Equine Vet Sci* 2005;25:113-117.
8. Cohen ND, Mealey RH, Chaffin MK, et al. The recognition and medical management of right dorsal colitis in horses. *Veterinary Medicine* 1995:687-691.
9. Bruton LL. Agents for control of gastric acidity and treatment of peptic ulcers. In: Gilman AG, Rall TW, Nies AS, Taylor P, eds. *Goodman and Gilman's The Pharmacological Basis of Therapeutics 8th ed.* Pergamon Press, 1990:897-913.