

# Neuromuscular Regulation of the Larynx and Nasopharynx in the Horse

Susan J. Holcombe, VMD, MS, PhD, Dipl. ACVS

An obstructive upper airway condition, such as dorsal displacement of the soft palate, often leads to poor performance among athletic horses. This condition may be caused by a primary dysfunction of the neuromuscular regulation of the soft palate. Author's address: Dept. of Large Animal Clinical Sciences, College of Veterinary Medicine, Michigan State University, East Lansing, MI 48824-1314. © 1998 AAEP.

## 1. Introduction

Obstructive upper airway disease is a major cause of poor performance in athletic horses. Dynamic obstructive lesions of the larynx or nasopharynx are frequently caused by neuromuscular dysfunction. The vagus and glossopharyngeal nerves primarily provide afferent innervation to the larynx and nasopharynx. Efferent innervation to the intrinsic laryngeal muscles is provided by branches of the vagus nerve. Branches of the trigeminal, glossopharyngeal, vagus, and hypoglossal nerves supply efferent innervation to the muscles that dilate and constrict the nasopharynx. Most of these nerves, excluding the recurrent laryngeal nerves, course through the guttural pouch, making them vulnerable to damage if the guttural pouch becomes inflamed or infected.

## 2. Larynx

The primary abductor of the arytenoid cartilages of the larynx is the cricoarytenoideus dorsalis muscle, which is innervated by the recurrent laryngeal nerve, a branch of the vagus nerve. Denervation atrophy of the cricoarytenoideus dorsalis muscle is caused by distal axonopathy of the recurrent laryngeal nerve,

resulting in laryngeal hemiplegia.<sup>1</sup> All of the intrinsic muscles of the larynx are innervated by the recurrent laryngeal nerve, except the cricothyroid muscle, which is innervated by the superior laryngeal nerve. Therefore, degeneration of the recurrent laryngeal nerve results in unilateral laryngeal dysfunction, including vocal fold collapse, dilation of the ventricle, and inability to abduct or adduct the arytenoid cartilage.

## 3. Nasopharynx

Dilation and stabilization of the nasopharynx are produced by muscles that attach to the hyoid arch, the intrinsic soft palate muscles, and the dorsal pharyngeal constrictor muscles. Muscles that insert on the hyoid arch increase upper airway size and stability, both when they are electrically stimulated and when they contract during inspiration.<sup>2</sup> Contraction of the geniohyoid, genioglossus, sternohyoid, and sternothyroid muscles produces a net ventral displacement of the hyoid arch that increases the lateral and ventral dimensions of the nasopharynx. These muscles all have increased electromyographic activity during phasic respiratory

---

## NOTES

activity, increased chemical drive, and augmented negative upper airway pressure.<sup>3</sup> The hyoepiglottic muscle attaches the base of the epiglottis to the hyoid bone, and when it contracts it pulls the epiglottis ventrally, toward the base of the tongue, further expanding the nasopharynx. The hyoepiglotticus, geniohyoid, genioglossus, and other intrinsic tongue muscles are innervated by the hypoglossal nerve.

#### 4. Dorsal Displacement of the Soft Palate

Dorsal displacement of the soft palate (DDSP) is an intermittent obstructive upper airway condition that occurs in athletic horses during high-intensity exercise (Fig. 1). The epiglottis is positioned dorsally to the soft palate and the caudal free margin of the soft palate closely approximates the larynx at the base of the epiglottis so that there is no communicating space between the nasopharynx and the oropharynx in horses. Dorsal displacement of the soft palate occurs when the caudal free margin of the soft palate is positioned dorsally to the epiglottis, creating a velopharyngeal obstruction. The pathogenesis of this condition remains obscure, and only fragmentary knowledge exists concerning the physiology of velopharyngeal patency in horses.

The position of the soft palate is determined by the coordinated activity of groups of antagonistic muscles, which include the levator veli palatini, tensor veli palatini, palatinus, and palatopharyngeus muscles (Figs. 2 and 3).<sup>4,5</sup> The levator veli palatini muscle elevates the soft palate during swallowing, vocalization, and eructation, and it facilitates oral ventilation.<sup>4,5</sup> The tensor veli palatini muscle expands the

nasopharynx during inspiration by tensing the palatine aponeurosis, thereby depressing the rostral half of the soft palate toward the tongue.<sup>4,5</sup> Impairing the function of the tensor veli palatini muscles by

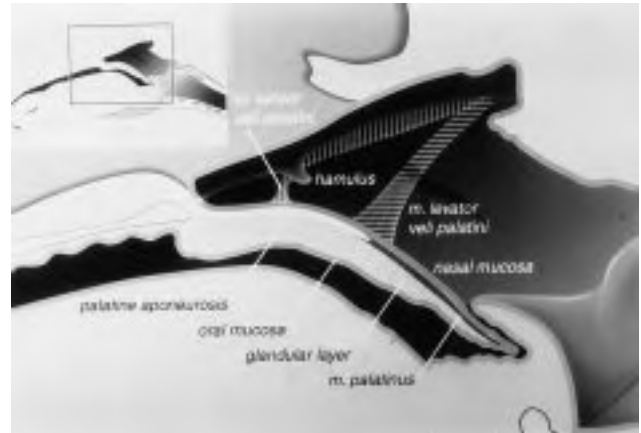


Fig. 2. Illustration of a transverse section through the larynx and nasal and oral portions of the pharynx in a horse. The hash marks of the tensor veli palatini and levator veli palatini muscles indicate that these muscles course beneath the nasopharyngeal mucosa.

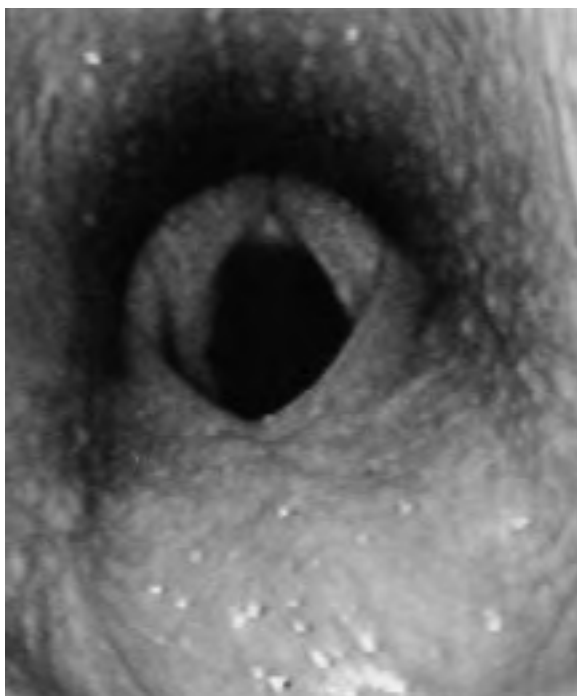


Fig. 1. Videoendoscopic image of the larynx and nasopharynx of a horse with DDSP.

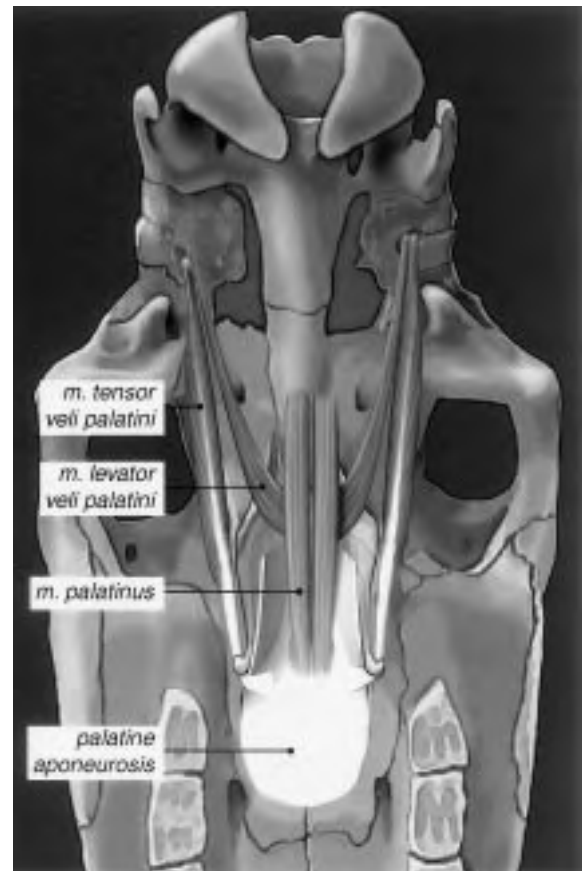


Fig. 3. Illustration of the ventral aspect of a horse's skull. Notice the muscles of the soft palate, the palatine aponeurosis, and the hamulus of the pterygoid bone (arrow).

## UPPER RESPIRATORY

transecting the tendon of the muscle prior to ramification in the palatine aponeurosis causes the rostral half of the soft palate to become flaccid, but dorsal displacement of the soft palate does not occur.<sup>6</sup>

### 5. Palatinus and Palatopharyngeus Muscles

The palatinus and palatopharyngeus muscles control the position of the caudal half of the soft palate, which is the portion of the soft palate that displaces dorsally and obstructs airflow in affected horses.<sup>4,5,7</sup> The palatinus muscle consists of two fusiform muscles that lie on either side of midline of the soft palate, beneath the nasopharyngeal mucosa, and extend caudally from the hard palate.<sup>8</sup> The muscles attach to the caudal aspect of the palatine aponeurosis and terminate near the caudal free margin of the soft palate. A small muscle bundle arising from the lateral aspect of each muscle continues a short distance caudodorsally into the palatopharyngeal arch.<sup>8</sup> The palatopharyngeus muscle originates from the palatine aponeurosis and the lateral border of the palatinus muscle. It travels caudally along the lateral wall of the nasopharynx to the pharyngeal raphe, forming part of the superior constrictor muscle group.<sup>8</sup> Contractions of the palatinus and palatopharyngeus muscles shorten the soft palate and depress the caudal portion toward the tongue.<sup>4,5,7</sup> Both the palatinus and palatopharyngeus muscles receive efferent motor innervation from the pharyngeal branch of the vagus nerve (Fig. 4). This nerve branches from the parent vagus nerve at the level of the cranial cervical ganglion and courses cranioventrally along the medial wall of the guttural pouch to

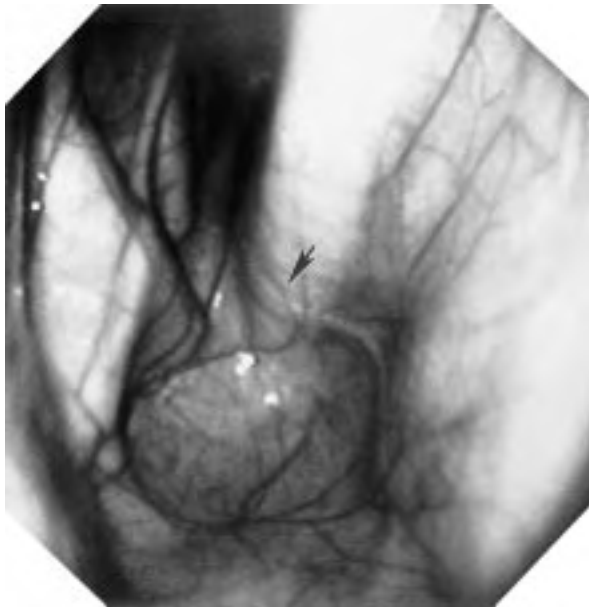


Fig. 4. Videoscopic view of the floor of the medial compartment of the guttural pouch. Notice the pharyngeal branch of the vagus nerve (arrow) as it courses across the longus capitis muscle.

the dorsal wall of the pharynx, where it ramifies in the pharyngeal plexus.

Blocking the pharyngeal branch of the vagus nerve bilaterally induces persistent DDSP in horses, implicating dysfunction of the pharyngeal branch of the vagus nerve and the palatinus and palatopharyngeus muscles in the pathogenesis of the clinical disease.<sup>9</sup> Measurements of upper airway mechanics made on horses with persistent DDSP produced by bilateral nerve block show that DDSP creates an expiratory nasopharyngeal obstruction. This observation has been made in clinical cases by Ducharme and others.<sup>10,11</sup> During exhalation, airflow causes the soft palate to billow, somewhat like a compliant sheet, obstructing expiratory airflow. As a result of this obstruction, expiratory pressure increases in an attempt to maintain expiratory airflow. Peak expiratory impedance also increases. Tracheal inspiratory pressures are less negative and inspiratory impedance decreases following bilateral nerve blockade. Previous studies have reported less negative peak tracheal inspiratory pressures in clinical cases of DDSP, suggesting that horses were breathing transorally. Based on clinical observation, it has been suspected that horses might open-mouth breathe during episodes of dorsal displacement of the soft palate. Transoral breathing would be a unique feature of this syndrome because horses generally are obligate nasal breathers. Horses had lower respiratory frequency and decreased minute ventilation, suggesting that horses with DDSP may not be able to maintain appropriate ventilation at high speeds.<sup>9</sup> Also, stride frequency:respiratory frequency coupling was altered by DDSP.<sup>9</sup>

### 6. Discussion

Interestingly, electromyographic measurements of the palatinus and palatopharyngeus muscles in normal horses exercising on a treadmill showed that these muscles are active and synchronous with respiration and that their activity increases as the exercise intensity and work of breathing increase. This information lends more credence to the hypothesis that DDSP is caused by a primary dysfunction of the neuromuscular regulation of the soft palate involving the pharyngeal branch of the vagus nerve and the palatinus and palatopharyngeus muscles. The pharyngeal branch of the vagus nerve is intimately associated with the retropharyngeal lymph node chain prior to ramifying in the pharyngeal plexus.<sup>8</sup> Retropharyngeal lymph node inflammation occurs frequently in young horses because of the high prevalence of viral upper respiratory tract diseases and secondary bacterial infections. In clinical cases of DDSP, the pharyngeal branch of the vagus nerve may be damaged in some yet unknown way, by local lymphadenopathy, inflammation, and infection. Rigorous efforts to decrease upper respiratory infections in horses by means of vaccination

## UPPER RESPIRATORY

and isolation of infected horses may help reduce the incidence of DDSP in horses. Horses exhibiting signs of DDSP may benefit from aggressive anti-inflammatory therapy and rest, which might help reduce or reverse the effects of local inflammation on nerve and muscle function.

## References

1. Cahill JI, Goulden BE. Equine laryngeal hemiplegia. Part 1. A light microscopic study of peripheral nerves. *NZ Vet J* 1986;34:161.
2. van Lunteren E, Haxhiu MA, Cherniack NS. Effects of tracheal airway occlusion on hyoid muscle length and upper airway volume. *J Appl Physiol* 1989;67(6):2296-2302.
3. Van de Graaff WB, Gottfried SB, Mitra J, et al. Respiratory function of hyoid muscles and hyoid arch. *J Appl Physiol* 1984;57(1):197-204.
4. Kuehn DP, Folkins JW, Cutting JW. Relationships between muscle activity and velar position. *Cleft Palate J* 1982;19:25-35.
5. Moon JB, Smith AE, Folkins JW, et al. Coordination of velopharyngeal muscle activity during positioning of the soft palate. *Cleft Palate Craniofac J* 1991;101:1332-1335.
6. Holcombe SJ, Derksen FJ, Stick JA, et al. Effect of bilateral tenectomy of the tensor veli palatini muscle on soft palate function in horses. *Am J Vet Res* 1997;58(3):317-321.
7. Trigos I, Ysunza A, Vargas D, et al. The San Venero Roselli pharyngoplasty: an electromyographic study of the palatopharyngeus muscle. *Cleft Palate J* 1988;25(4):385-388.
8. Hare WCD. Equine respiratory system. In: Getty R, ed. *Sisson and Grossman's the anatomy of domestic animals*, 5th ed. Philadelphia: Saunders, 1975;504-511.
9. Holcombe SJ, Derksen FJ, Stick JA, et al. Bilateral nerve blockade of the pharyngeal branch of the vagus nerve produces persistent soft palate dysfunction in horses. *Am J Respir Crit Care Med* 1997;155(4):A412.
10. Rehder RS, Ducharme NG, Hackett RP, et al. Measurement of upper airway pressures in exercising horses with dorsal displacement of the soft palate. *Am J Vet Res* 1995;56(3):269-274.
11. Roethlisberger-holm K. Tracheal pressure in horses with signs of dorsal displacement of the soft palate. *Equine Vet J Suppl* 1995;18:70-75.