

In: **49th Annual Convention of the American Association of Equine Practitioners, 2003, New Orleans, Louisiana**, (Ed.)

Publisher: American Association of Equine Practitioners, Lexington KY

Internet Publisher: Publisher: International Veterinary Information Service ([www.ivis.org](http://www.ivis.org)), Ithaca, New York, USA.

## **What MRI is Teaching us about Navicular Disease** (21-Nov-2003)

**R. K. Schneider, P. R. Gavin and R. L. Tucker**

Veterinary Teaching Hospital, Washington State University, Pullman, WA, USA.

### **1. Introduction**

Since 1997, magnetic resonance (MR) imaging has been used at Washington State University to evaluate horses with lameness problems localized to the distal limb [a] [1,2]. MR creates a slice by slice, grayscale image of tissue protons (hydrogen nuclei) under the influence of a magnetic field, and the disruption of these protons by radio frequency waves is measured and recorded to create an electronic image [a] [1-3]. The high-resolution images can demonstrate structural and physiologic alterations within the tissues early in the course of the disease, before they are detectable by most other imaging modalities [3]. MR is a frequently used diagnostic imaging modality for evaluation of musculoskeletal injuries in humans. It is not only valuable for imaging ligaments and tendons but can also demonstrate bone abnormalities in cases where conventional radiographs are normal [a] [3,5].

MR has proven to be a valuable tool for making specific diagnoses in horses with performance limiting lameness problems [a]. It has been particularly advantageous for foot problems because it has allowed us to evaluate soft tissue structures in the horse's foot that could not previously be seen with other imaging techniques. It also allowed us to obtain sectional images of the horse's foot, which made it possible to see internally into both the bones and the soft tissue structures. Before this, radiographs were the only images used routinely to evaluate horses' feet, and as a result, veterinarians were limited to evaluating osseous changes [6]. Ultrasound has had limited use in the foot because the keratinized hoof wall, frog, and sole limits contact with ultrasound scan heads and does not allow good images to be obtained of the important soft tissue structures [7]. Nuclear scintigraphy has been used to image the foot, but its use is also limited because of poor images of soft tissues as well as limitations in detecting bone abnormalities when a relatively small amount of bone is involved. MR has added to our knowledge of navicular disease, in large part, because for the first time we can see into the horse's foot.

### **2. MR Equipment and Technique**

The magnet currently used at Washington State University is a 1.0 Tesla Philips Gyroscan [b] that has one end modified to allow the horses' fore or rear limbs to be placed far enough into the flared opening to allow imaging of the distal extremities. This is because of a flared end short bore gantry on the end of the magnet that allows access for the large upper limbs of the horse. General anesthesia of the horse is required. The techniques used for the horse's feet have been described and are beyond the scope of this paper [a] [1,2,8]. The imaging techniques developed at Washington State University were shared with researchers at Newmarket, England, and have since been published with minor modifications [8]. The imaging sequences that have been routinely used for the feet are the dual-echo (proton density and T2-weighted), short tau inversion recovery (STIR), spectral inversion (SPIR), and three-dimensional (3D) gradient echo sequences. STIR sequences have proven to be especially valuable because they allow us to detect fluid in both soft tissues and bone. Small amounts of fluid are present at sites of inflammation. The proton density sequences provide the clearest images and anatomic detail, especially useful for evaluating ligaments and tendons. The gradient echo sequences were implemented to allow us to use a smaller interslice gap when axially sectioning the foot, decreasing the possibility of missing defects in the navicular bone that could occur with the larger interslice gaps required for the dual-echo and STIR sequences. Techniques for imaging of the equine foot will continue to evolve with increasing experience with MR.

Sectioning of the foot is also important to allow us to see pathologic changes. Axial (transverse) and sagittal (longitudinal) sections are routinely used for MR of the equine foot. Because MR allows us to section the foot at any angle, improvements in MR imaging in the future may occur as a result of sectioning the foot at specific angles to detect suspected abnormalities.

### 3. Case Selection

Navicular disease is one of the most common causes of performance limiting lameness in many types of athletic horses [9]. Despite the high incidence of the disease, our understanding of the problem is relatively limited. The observations made about navicular disease in this paper come from our experience with MR imaging [c] of more than 150 horses with clinical signs of navicular disease. Some horses had developed clinical signs within 6 mo of MR imaging, whereas others had a chronic history of lameness. Most of these horses did not have radiographic findings that have been correlated with navicular disease, i.e., loss of the corticomedullary junction or lytic defects in the flexor cortical bone on the skyline projection. Some horses did have these abnormalities, and MR imaging was performed to determine if there was an adhesion between the navicular bone and the deep digital flexor tendon.

### 4. Etiology and Pathogenesis

Equine practitioners have long suspected that there were multiple problems in the foot that caused similar clinical signs. Because of the limitations of radiographs, many causes of bilateral foot pain were recognized and diagnosed as navicular disease. MR observations indicate that there are different problems that cause pain in the heel of the foot that, without MR imaging, would be diagnosed as navicular disease. MR imaging has allowed us to begin to differentiate some of these problems from navicular disease [c]. Gaining knowledge is a slow process and we are still on the steep phase of the learning curve with MR imaging of the horse's foot. However, our experience to date does allow us to speculate on possible causes or factors that may contribute to the development of navicular disease.

Navicular disease is not the same in all horses. The old theory that the disease starts as a bursitis and progresses into the bone [10] does not seem to be supported by MR observations. There are many horses that have navicular disease based on finding of diffuse fluid in the navicular bone that do not have increased fluid in the navicular bursa (Fig. 1). The concept that degeneration of the flexor cortex of the navicular bone results from inflammation in the bursa, sustained abnormal pressure between the navicular bone and the deep digital flexor tendon, and erosion of the fibrocartilage on the flexor surface exposing the subchondral bone [11,12] may well occur in some horses. The cause of the chronic progressive degeneration of the navicular bone may be different in different horses. Based on MR observations of abnormal fluid within the navicular bone in horses with recent onset of clinical signs and observations of bone pathology within the medullary cavity, [13] it is possible that degeneration of the flexor cortex may be preceded by inflammation within the medullary cavity in some horses. Fluid in the navicular bone was the most common abnormality observed in a group of 30 horses with recent onset of clinical signs [c].

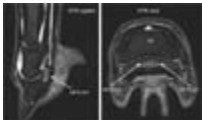

Figure 1. STIR images from a horse with clinical signs of navicular disease. The arrows point to the white area that indicates the presence of diffuse fluid within the medullary cavity of the navicular bone. STIR sequences suppress fat allowing fluid to be detected in bones, synovial spaces, tendons, and ligaments. - To view this image in full size go to the IVIS website at [www.ivis.org](http://www.ivis.org) . -

The cause of this fluid remains to be determined. It may be edema as a result of a remodeling response in the bone as has been described based on histopathologic observations of the navicular bones from horses with the disease [11]. It may be hemorrhage or synovial fluid. It is probable this fluid is accumulating in the bone as a result of inflammation. Excessive fluid is not present in the navicular bone of normal horses. The amount of fluid signal in the navicular bone does seem to correlate with clinical signs. The most fluid is usually found in the bone of the lamest leg. More knowledge is needed before the cause of the fluid in the navicular bone is understood. However, currently it seems to be one of the early detectable signs that an inflammatory process has started in the navicular bone.

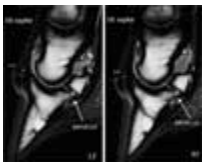


Figure 2. T2-weighted sagittal sequences from a horse with signs of navicular disease. The impar ligament is thickened and irregular bilaterally. T2-weighted sequences provide the best anatomic detail for evaluating soft tissue structures. - To view this image in full size go to the IVIS website at [www.ivis.org](http://www.ivis.org) . -

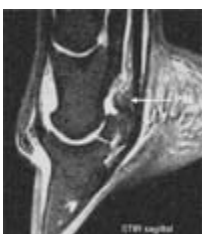

Figure 3. A sagittal STIR image from a horse with clinical signs. The proximal suspensory ligament is abnormally thick and irregular. Viewing multiple sections from lateral to medial across the width of the foot allows one to assess severity of the abnormalities observed. - To view this image in full size go to the IVIS website at [www.ivis.org](http://www.ivis.org) . -

Some horses seem to have desmitis of the supporting soft tissues of the navicular bone, the impar ligament, and the proximal suspensory ligament of the navicular bone (Fig. 2 and Fig. 3). It is not known if these horses will progress to develop inflammation and degeneration of the navicular bone. We currently separate these horses from those with navicular bone involvement, although these horses may progress to develop inflammation in the navicular bone, especially at the origin of the impar ligament on the distal border of the navicular bone.

Some horses present with bursitis of the navicular bursa based on finding increased fluid in the bursa on MR images (Fig. 4). There also appears to be abnormal tissue in the bursa at its proximal aspect in some horses that may represent fibrous scar tissue from chronic inflammation. Bursitis is not a common finding in many horses, which suggests that it is not the initiating cause of navicular disease in the majority of cases.

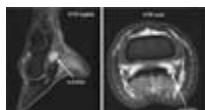


Figure 4. STIR sequences, axial and sagittal, clearly demonstrating increased fluid in the navicular bursa. Viewing multiple sections, especially at the lateral and medial borders of the fluid distended bursa, allows an assessment to be made of the amount of fluid that is present. - To view this image in full size go to the IVIS website at [www.ivis.org](http://www.ivis.org) . -

Some horses have tendinitis of the deep digital flexor (DDF) tendon that occurs in the area of the tendon proximal to the navicular bone and extends up the tendon to above the middle of the proximal phalanx (Fig. 5). In several horses, this has been the primary finding, with relatively few other abnormalities on MR images. These horses may have a completely different etiology from horses with navicular disease. For example, hyperextension of the distal interphalangeal joint as a result of forceful elevation of the toe of the foot may cause chronic or acute tearing of the DDF tendon fibers. These horses have treatment options different from horses with degeneration of the navicular bone (see Treatment) and should be considered a different syndrome than navicular disease when the navicular bone is not involved.

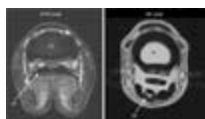


Figure 5. An axial STIR image (left) of a horse with irregular borders and abnormal fluid signal within the DF tendon proximal to the navicular bone. A T2-weighted axial image of a different horse that shows an abnormal signal in the DF tendon in the middle of the proximal phalanx. - To view this image in full size go to the IVIS website at [www.ivis.org](http://www.ivis.org) . -

Many horses have more than one abnormality observed on MR images. Navicular disease may result from more than one cause and more than one focus of initial inflammation. It also suggests that some of the abnormalities may have a common etiology or are inter-related. More possibilities should be considered than the causes described in the literature: the biomechanical theory based on sustained pressure between the DDF tendon and the navicular bone, [11] the vascular theory that relates the cause to an interruption of blood supply, [13,14] and the theory that chronic bursitis leads to fibrocartilage degeneration over the flexor cortex and chronic pathologic changes in the bone that are similar to osteoarthritis [14]. Chronic or acute strain on the supporting soft tissues of the navicular bone, the impar and proximal suspensory ligaments, occurs in the caudal phase of the stride as the horse is pushing off the foot. Strain on the ligaments or their attachments to the bone can result in injury, inflammation, and pain. Strain injury to the ligament attachments to the navicular bone may cause local inflammation in the bone that is similar to what occurs in the proximal sesamoid bone when collagen fibers are pulled from the bone at the attachment of the branches of the suspensory ligament. Sesamoiditis is a term that has been used to describe the radiographic abnormalities of lysis and proliferation that occur in the proximal sesamoid bone secondary to injury to the ligament insertion. Like navicular disease, it can cause chronic lameness in performance horses that is difficult to resolve. Sesamoiditis of the distal sesamoid secondary to injury to the collagen fibers at their attachment to the bone is another possible cause of navicular disease. The attachment of the impar ligament to the navicular bone may be more susceptible to injury, based on the frequent observation of fluid in the distal one-third of the bone. Considering the complexity of the interaction of the distal interphalangeal joint, navicular bone, navicular bursa, and the DDF tendon, it is not surprising that there may be involvement of more than one structure as a result of this type of loading. Strain loading of these structures when the horse is pushing off the front foot may explain why horses with navicular disease are short strided. It also may be why shortening the toe to ease break over is beneficial for some horses.

Direct concussion to the frog, resulting in excessive force on the navicular bone, may cause hemorrhage in the medullary cavity. Osseous contusions have been observed in horses [a] and humans [3,4]. This possibility should be considered in horses with an acute history, and MR findings of fluid in the medullary cavity of the navicular bone with little or no soft tissue involvement.

The etiology can only be speculated until more information is available. Correlation of MR findings with histopathologic evaluation is a necessary step. Studies comparing age- and use-related controls to affected horses might help to determine the significance of some MR observations. More experience with MR imaging of clinical cases is essential as we seek to better understand the pathogenesis of this important disease.

## 5. Diagnosis

### Navicular Disease

It is clear that MR imaging can be a valuable tool to differentiate navicular disease from other causes of lameness in the foot. In the future, accurate diagnosis in horses with early clinical signs of navicular disease may require MR imaging. Finding excessive fluid in the navicular bone, especially diffuse fluid in the medullary cavity, allows us to confirm navicular disease as the cause of the horse's problem. The fluid is not present in normal horses. Unlike radiographic changes, which for the most part do not correlate with clinical signs, fluid in the bone on MR was observed to correlate with clinical signs. The most fluid and most obvious abnormalities were in the lamest leg. The STIR images proved necessary to document abnormal fluid in the navicular bone. We currently use the diagnosis of navicular disease only when fluid is present in the bone.

### Desmitis of Supporting Ligaments

Currently, horses with impar ligament and/or proximal suspensory ligament desmitis are considered a separate diagnosis from horses with navicular disease. It is not clear if these horses will progress to develop inflammation and degeneration of the navicular bone, although we have observed progression in one horse. Currently, treatments are similar. Because initial treatment may someday be different and because we are not sure of progression, we currently separate these horses from those with abnormal fluid in the navicular bone. There are horses that have both fluid in the bone and desmitis of the supporting ligaments. These horses are diagnosed with navicular disease.

### Deep Digital Flexor Tendinitis

One of the most important observations from MR was finding tendinitis in the DDF tendon proximal to the navicular bone. This observation also correlated with the lameness; horses were more lame in the limb with the most severe abnormalities in the tendon. Tendinitis of the deep flexor tendon should be a separate diagnosis in horses with little or no involvement of the navicular bone. The lameness in these horses will improve significantly when the digital flexor tendon sheath is injected with local anesthetic [d]. Injecting the sheath did not desensitize the palmar digital nerves, but this can occur if local anesthetic leaks subcutaneously from the injection site. Skin sensation seems to be an effective way of determining if the nerve has been blocked. Blocking the digital flexor tendon sheath may be a technique that can be used to diagnose DF tendinitis without MR. More clinical cases, where MR has confirmed the presence tendinitis, need to be evaluated before we can be confident of this diagnostic technique. It is important to understand that other structures (like the distal sesamoidean ligaments) can be desensitized by injecting local anesthetic into the sheath; thus, this technique is not specific for the DDF tendon. The sheath extends distally into the foot along the DDF tendon and comes close to the proximal border of the navicular bursa (Fig. 6). It is possible that other structures within the foot may also be blocked. MR axial sections of horses that have been injected in the digital flexor tendon sheath demonstrate that the sheath does not contact the digital nerves anywhere along its course, [e] which is why the injection does not ablate nerve function.

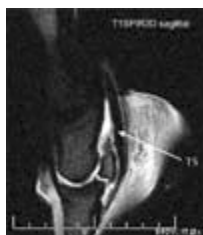

Figure 6. T2-weighted image of a sagittal section of the foot of a normal horse after injection of the digital flexor tendon sheath with 10 ml of fluid. The distal extent of the sheath comes close to the navicular bone and bursa in the foot. Injection of the sheath allows local anesthetic or anti-inflammatory medications to reach the area of the DF tendon where tendinitis has been frequently observed with MR imaging. - To view this image in full size go to the IVIS website at [www.ivis.org](http://www.ivis.org) . -

DDF tendinitis has been observed in locations other than proximal to the navicular bone. Tendinitis does occur directly over the flexor surface of the navicular bone. A small number of horses have abnormal signal in the tendon distal to the navicular bone. Only two horses have had abnormal signal and fluid at the distal insertion of the tendon on the third phalanx. MR imaging is necessary to observe these abnormalities. Tendinitis in all horses is not the same; it is observed in horses with fluid in the navicular bone or in the navicular bursa. Sorting out which problem, tendinitis or navicular bone inflammation, is causing the lameness is difficult and will require experience with many more cases.

### Distal Interphalangeal Joint Arthritis

Increased fluid was observed in the distal interphalangeal joint in some of the horses (Fig. 7). Increased fluid comes from inflammation somewhere in the joint and was considered to be a sign of arthritis. Most of these horses also had abnormal findings in the navicular bone or its supporting soft tissues. It has always been difficult to differentiate horses with arthritis of the distal interphalangeal joint from horses with navicular disease. They are related problems because the navicular bone and its attaching ligaments are at the palmar aspect of the joint. Forces that would cause increased strain on the navicular bone or ligaments would also cause hyperextension of the joint. Diagnosing arthritis of the distal interphalangeal joint will be improved with MR but it will still be difficult to separate it from navicular disease in some horses. In some horses it is very likely to be part of the same problem.

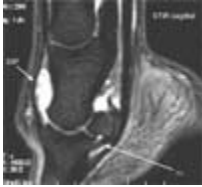


Figure 7. A STIR sequence image, sagittal section, from a horse with clinical signs of navicular disease. Increased fluid is observed in the distal interphalangeal joint. There is dorsal and proximal distension of the joint capsule. Viewing sequential sections of the foot from its lateral to medial border allows one to accurately assess the amount of fluid distension in both the dorsal and palmar pouches of the joint. - To view this image in full size go to the IVIS website at [www.ivis.org](http://www.ivis.org) . -

Increased fluid was also observed in the navicular bursa in some horses and is a sign of inflammation of the bursa. MR imaging is the only current method of accurately making this diagnosis. Based on the relatively low frequency of this observation in horses with recent onset of clinical signs, it seems that navicular bursitis is not a common diagnosis early in the course of the disease. In more chronic cases, abnormal tissue has been observed in the proximal navicular bursa in addition to fluid. Fibrous tissue may occur in horses as a result of chronic inflammation. Adhesion of the deep flexor tendon to the navicular bone has been recognized as a serious consequence in horses with chronic navicular disease for many years. Fibrous scar tissue between the proximal suspensory ligament of the navicular bone and the DDF tendon can restrict the movement of the tendon and may be a chronic source of pain in some horses. It appears that many horses have navicular disease with involvement of the bone and no abnormalities in the bursa.

### Multiple Abnormalities

Frequently, multiple MR abnormalities were observed in horses with clinical signs of navicular disease. It was not always possible to make a primary diagnosis; however, most of these horses had excessive fluid in the navicular bone and were diagnosed with navicular disease. Based on the variation observed, many more horses with navicular disease will have to be evaluated with MR before patterns and combinations that are of clinical importance can be established. It is likely that there is more than one cause of inflammation in the navicular bone that results in chronic pain and progressive degeneration of the bone.

Not all horses with clinical signs of navicular disease had abnormalities observed in the navicular bone, navicular bursa, DDF tendon, or the supporting ligaments of the bone. The following problems were diagnosed as navicular disease in different horses prior to MR imaging: chronic laminitis with mild rotation of P-3, early bilateral osteoarthritis of the proximal interphalangeal joint, palmar (caudal) heel lamina pain, and bilateral desmitis of the straight sesamoidean ligament proximal to its insertion on P-2. These horses were diagnosed with navicular disease because they had bilateral forelimb lameness that switched to the opposite leg after a palmar digital nerve block. Horses with chronic laminitis had increased fluid, irregularity, and thickening of the lamina, and bone proliferation on the distal margin of P-3 observed with MR imaging. A palmar digital nerve block frequently desensitizes the sole of the foot, which explains why in horses with this problem, the lameness will switch to the opposite forelimb. Horses with bilateral early osteoarthritis of the proximal interphalangeal joint had increased fluid in the joint on MR imaging. Horses with desmitis of the straight sesamoidean ligament had abnormal fluid in the ligament proximal to its insertion on P-2 [15]. One horse was diagnosed with palmar (caudal) heel pain caused by chronic inflammation in the lamina over the medial and lateral wings of P-3. This was observed on MR imaging; there was irregularity, thickening, and fluid in the lamina along the palmar wings of the third phalanx. More horses with these types of changes were expected based on clinical observations of horses with bilateral palmar heel pain. This diagnosis may be made more frequently with different sectioning techniques for evaluating the lamina circumferentially around P-3.

MR imaging is invaluable for differential diagnosis of horses with clinical signs of navicular disease. However, in some, the diagnosis could have been made using other methods. For example, in horses with bilateral arthritis of the proximal interphalangeal joint, the lameness did improve significantly after an intra-articular injection of local anesthetic, or in horses with straight sesamoidean ligament desmitis, evaluation with high-resolution ultrasound would have helped make a specific diagnosis [15]. These differential diagnoses and diagnostic techniques should be considered when evaluating horses with clinical signs of navicular disease.

It has been stated that all horses with navicular disease are responsive to hoof tester pressure over the middle one-third of the

frog [16]. Our experience, based on clinical observations on horses with navicular disease that had MR imaging, is in agreement with this observation. All horses with navicular disease were sensitive to hoof tester pressure over the frog. However, so were horses with DDF tendinitis, navicular bursitis, and impar ligament desmitis. More importantly, while this is a consistent clinical finding, the corollary is not true. Not all horses with sensitivity to hoof testers over the frog have navicular disease. There are some horses sensitive to hoof testers who are not lame or have lameness problems that are located more proximal in the limb.

Previously the diagnosis of navicular disease has been based for the most part on clinical signs because of poor correlation with observations from radiographs. MR imaging now allows us to make this diagnosis with more confidence and differentiate multiple causes of similar clinical signs. As this technology becomes more available and our experience with it increases, it will become the preferred imaging technique for horses with a clinical diagnosis of navicular disease. Increased experience will allow us to determine clinical significance and prognosis for horses with different MR findings.

## **6. Treatment**

MR imaging has affected treatment of horses with navicular disease. Horses with DDF tendinitis have increased options for treatment that have not previously been used or have not been routinely recommended for horses with navicular disease. MR imaging improves case selection for treatments that have traditionally been used, but have at times resulted in an inconsistent response.

Horses with DDF tendinitis proximal to the navicular bone improve when anti-inflammatory medications, like hyaluronic acid and methylprednisolone acetate (Depo-Medrol), are injected into the digital flexor tendon sheath [d]. Medications injected into the sheath are absorbed by the tendon, decreasing inflammation and pain in the tendon. This treatment has not been adequately evaluated in a large number of horses with long-term follow-up. However, some horses have had a long-term response to this treatment. The digital flexor tendon sheath extends distally along the tendon almost to the navicular bone [e]. Medication in the sheath will reach the area of tendinitis in the DDF tendon that has been observed in horses with clinical signs of navicular disease. These horses do not usually have effusion of the digital flexor tendon sheath. It can be difficult to inject the sheath when no fluid is present using standard techniques. The sheath is injected distal to the palmar annular ligament of the metacarpophalangeal joint below the base of the proximal sesamoid bone. A 1.5-in, 18-gauge needle is directed proximally along the lateral border of the flexor tendons. Fluid is frequently obtained, even in non-distended sheaths. Ease of injection also confirms accurate placement of the needle into the sheath.

Currently, this treatment has improved the lameness in every horse in which it has been used. Some horses have continued in performance for 2 yr without a second treatment. The long-term response may occur because decreasing the pain allows the horse to stretch the tendon to a functional length. Some horses have improved, but lameness has persisted and these horses have not been able to return to performance.

Rest is not a treatment traditionally recommended for horses with navicular disease. It is a treatment that should perhaps be considered for some horses. Horses with acute tendinitis of the DDF tendon or acute desmitis of the supporting ligaments to the navicular bone may benefit from a rest and rehabilitation program that gives them the opportunity to heal before returning to performance.

Horses with navicular disease have been treated by injecting anti-inflammatory medications into the distal interphalangeal joint or the navicular bursa. MR imaging allows us to better select cases for each of these treatments. Horses with abnormalities in the impar ligament or navicular bone with increased fluid in the distal interphalangeal joint may respond to injection of the joint. Horses with fluid and inflammation in the navicular bursa are candidates for injection of the bursa. Since MR imaging to evaluate horses with navicular disease was initiated at WSU, we have started to inject horses in the bursa with hyaluronic acid and cortisone (methylprednisolone acetate). Some horses have markedly improved with this treatment and successfully returned to performance. More follow-up on additional cases is needed before the success of this treatment can be accurately determined. Injection of the bursa as a treatment has been around for a long time. The inconsistent or poor response to this treatment in some horses can be understood now that we recognize that navicular bursitis may not be as common as other abnormalities observed in horses with navicular disease [c]. Being able to select horses that are candidates for this treatment may improve the success of this procedure.

MR imaging also is valuable for selecting cases that are candidates for palmar digital neurectomy. Horses that have adhesion of the DF tendon to the navicular bone are not good candidates for neurectomy because they frequently develop tendinitis of the DF tendon proximal to the desensitized area within a few weeks of being nerved. MR imaging allows us to evaluate both the bone and the tendon. Horses with adhesion between the tendon and the bone can be detected with MR imaging. Because the DDF tendon contacts the flexor surface of the navicular bone during MR imaging, observing the adhesion is not always easy. In these cases, injection of fluid into the bursa can increase the space between the tendon and the bone, allowing adhesions to be visualized. MR imaging also helps identify horses that should be good candidates for this procedure because the MR findings around the navicular bone are relatively mild. With increasing experience, MR findings may help determine criteria on MR that helps us better select horses that are and are not good candidates for this procedure.

No new treatments for horses with navicular disease have yet been developed. Treatment is still aimed at managing horses with the problem using corrective shoeing and anti-inflammatory medications. However, as MR imaging increases our knowledge about navicular disease, early diagnosis, new treatments, or better case selection for current treatments will hopefully follow.

## 7. Conclusions

1. MR is a valuable imaging modality for horses with clinical signs of navicular disease.
2. MR imaging has allowed us to differentiate the causes of clinical signs of navicular disease based on observing inflammation in different anatomic structures in the foot of the horse.
3. DDF tendinitis proximal to the navicular bone is a clinical problem that should be considered a differential diagnosis for horses with navicular disease.
4. Forces that create tensile strain on the impar ligament, navicular bone, and proximal suspensory ligament may contribute to development of navicular disease. Inflammation in the bone may result from tensile injury to the collagen fibers at their insertion in the bone.
5. Injection of the DDF sheath seems to be an effective treatment in some horses with DDF tendinitis.
6. MR imaging may target cases that can be treated by injecting the navicular bursa.
7. Accurate diagnosis of navicular disease, especially in acute cases before radiographic abnormalities develop, may require MR imaging.

## Footnotes

[a] Zubrod CJ, Schneider RK, Tucker RL, et al. Diagnosis of subchondral bone damage using magnetic resonance imaging in eleven horses. *J Am Vet Med Assoc*. 2003 (in press).

[b] Philips Medical Systems, Best, The Netherlands

[c] Schneider RK, Tucker RL, Gavin PG, et al. MR imaging of the foot in horses with recent onset of clinical signs of navicular disease without radiographic abnormalities: 30 cases. *J Am vet Med Assoc* 2003 (in press).

[d] Schneider RK. Injection of the digital flexor tendon sheath for diagnosis and treatment of tendon and ligament problems in the equine distal limb. 2003 (in press).



[e] Richter MC, Schneider RK, Gavin PR (unpublished data) 2003.

## References

1. Mehl ML, Tucker RL, Ragle CA, et al. The use of MRI in the diagnosis of equine limb disorders. *Equine Pract* 1998; 20:14-17.
2. Kraft SL, Gavin PR. Physical principles and technical considerations for equine computed tomography and magnetic resonance imaging. *Vet Clin North Am [Equine Pract]* 2001; 17:115-130.
3. Lynch TC, Crues JV, Morgan FW, et al. Bone abnormalities of the knee: prevalence and significance at MR imaging. *Radiology* 1989; 171:761-766.
4. Vellet AD, Marks PH, Fowler PJ, et al. Occult posttraumatic osteochondral lesions of the knee: prevalence, classification, and short-term sequelae evaluated with MR imaging. *Radiology* 1991; 178:271-276.
5. Kapelov SR, Teresi LM, Bradley WG, et al. Bone contusions of the knee: increased lesion detection with fast spin-echo MR imaging with spectroscopic fat saturation. *Radiology* 1993; 189:901-904.
6. Turner TA, Kneller SK, Badertscher RR, et al. Radiographic changes in the navicular bones of normal horses. In *Proceedings Am Assoc Equine Pract* 1986; 32:309-313.
7. Busoni V, Denoix JM. Ultrasonography of the podotrochlear apparatus in the horse using a transcuneal approach: technique and reference images. *Vet Radiol Ultrasound* 2001; 46:534-540.
8. Dyson S, Murray R, Schramme M, et al. Magnetic resonance imaging of the equine foot: 15 horses. *Equine Vet J* 2003; 35:18-26.

9. Stashak TS. Navicular syndrome, the foot. In: Stashak TS, ed. Adam's lameness in horses, 5th ed. Philadelphia: Lippincott Williams and Wilkins, 2002; 684.
10. Adams OR. Navicular disease In: Adams OR, ed. Lameness in horses, 3rd ed. Philadelphia: Lea and Febiger, 1974; 260.
11. Pool RR, Meagher DM, Stover SM. Pathophysiology of navicular syndrome. In: Yovich JV, ed. Veterinary clinics of north america, equine practice. Philadelphia: WB Saunders Co, 1989; 109-129.
12. Wright IM, Kidd L, Thorp BH. Gross, histological and histomorphometric features of the navicular bone and related structures in the horse. Equine Vet J 1998; 30:220-234.
13. Colles C, Hickman J. The arterial supply of the navicular bone and its variations in navicular disease. Equine Vet J 1977; 9:150-154.
14. Rijkenhuizen A, Nemeth F, Dik K, et al. The arterial supply of the navicular bone in adult horses with navicular disease. Equine Vet J 1989;21:418-424.
15. Schneider RK, Tucker RL, Habegger SR, et al. Desmitis of the straight sesamoidean ligament as a cause of lameness in 9 horses. J Am Vet Med Assoc 2003; 222:973-977.
16. Stashak TS. Navicular syndrome, the foot. In: Stashak TS, ed. Adam's lameness in horses, 5th ed. Philadelphia: Lippincott Williams and Wilkins, 2002; 667.

All rights reserved. This document is available on-line at [www.ivis.org](http://www.ivis.org). Document No. P0627.1103. This manuscript is reproduced in the IVIS website with the permission of the AAEP [www.aaep.org](http://www.aaep.org)

	<b>American Association of Equine Practitioners</b>		
	<b>Future Conventions :</b>		<i>Dec. 4-8, 2004 - Denver, CO.</i>
			<i>Dec. 3-7, 2005 - Seattle, WA.</i>
			<i>Dec. 2-6, 2006 - San Antonio, TX.</i>
	<i>For more information go to <a href="http://www.aaep.org/">http://www.aaep.org/</a></i>		

*Leading the way in providing veterinary information*

