

In: **Recent Advances in Small Animal Reproduction**, P. W. Concannon, G. England and J. Verstegen (Eds.)  
Publisher: International Veterinary Information Service ([www.ivis.org](http://www.ivis.org)), Ithaca, New York, USA.

## Vaginal Edema and Vaginal Fold Prolapse in the Bitch, Including Surgical Management ( 10-Apr-2001 )

**A. C. Schaefers-Okkens**

Department of Clinical Sciences of Companion Animals, Faculty of Veterinary Medicine, University of Utrecht, Utrecht, The Netherlands

### Introduction

Vaginal prolapse occurs in several species, such as cattle, goats and sheep. In these species we refer to a true vaginal prolapse that involves the entire vaginal wall, and sometimes the bladder as well. In the bitch, this type of true vaginal prolapse is a very rare condition. If a true prolapse occurs in the bitch other organs such as the bladder, but also the uterine body and/or distal part of the colon may also be present in the prolapse [1]. More frequently, in the bitch an edematous swelling of the vaginal mucosa immediately cranial to the urethral orifice and expanding caudally over the urethral orifice, may develop under the influence of estrogen. This may become large enough to protrude outside the vulvar lips (Fig. 1).




Figure 1. Vaginal edema in 2 bitches observed during pro-estrus/estrus: a modest edema, which is observed quite often during this period of the cycle (left side) and a more extensive form of edema/fold prolapse, which may cause mating problems (right side). [From: 10] - To view this image in full size go to the IVIS website at [www.ivis.org](http://www.ivis.org) . -

This condition has been traditionally referred to as vaginal hyperplasia and vaginal prolapse. However, because it is in fact not a true organ prolapse and hyperplasia and since the involved tissue is extremely edematous, it is better to use the terms vaginal edema and vaginal fold prolapse [2]. A vaginal fold prolapse is a condition which may occur in the young bitch during the first or second follicular phase under estrogen influence [3-5] and may reoccur at each subsequent estrus, if the bitch is not properly treated. In exceptional cases, a vaginal fold prolapse may occur at the end of pregnancy. Although considered to occur infrequently, a survey of 143 bitches with vaginal diseases included 24 bitches with vaginal fold prolapse [6]. Little is known about hereditary aspects. It appears that the incidence of the condition is higher in brachycephalic breeds, such as the Boxer, Bull Mastiff and Mastino Napolitano, but the condition is also observed in Dalmatians and Dobermanns.

### Clinical Manifestations

Vaginal edema, not expanding outside the vulvar lips, is frequently present during the follicular phase of the bitch and regresses under the influence of progesterone. If the edema expands, a swelling varying from a small bulge to a pear-shaped mass protruding from the vulva can be observed. Despite the fact that the urethra is always displaced distally due to the enormous edema of the mucosa, dysuria occurs only occasionally. The ventral part of the vaginal mucosa is involved in the majority of vaginal fold prolapses. In some cases the lateral and dorsal parts of the vaginal mucosa, and thus the entire circumference, are involved as well. In these cases a doughnut-shaped appearance is noted. The protruding mass of the prolapse is vulnerable to trauma, ulceration, and self-mutilation and can interfere with natural mating.

### Differential Diagnosis

Vaginal edema and vaginal fold prolapse can be confused with a tumor, such as a steeled fibroma or leiomyoma. These types of tumors may be observed partly outside the vulva during estrus in the older bitch, while vaginal fold prolapse is generally observed during the bitch's first or second estrus. In addition, the prolapse originates from the ventral floor of the vagina cranial to the urethral orifice and it regresses at least partially during the luteal phase, which is not the case with tumors. In addition, a true vaginal or a uterine prolapse, which mainly occurs during parturition or shortly after, can be confused with a vaginal floor prolapse.

## Treatment

Treatment depends on the extent of the fold prolapse, whether one is dealing with a breeding or non-breeding bitch and whether or not the prolapse is present during estrus or at the end of pregnancy. If in exceptional cases a fold prolapse develops just prior to whelping, there is in general no need for treatment and parturition can take place without problems [7]. In pro-estrus or estrus bitches, if a fold prolapse is barely outside the vulva or protrudes intermittently and the owner wants to spay the dog, the edema will generally recede during the luteal phase and the bitch may be ovariectomized, preferably during anestrus. Ovariectomy during estrus enhances the risk for hemorrhages during surgery and if performed during the luteal phase pseudopregnancy symptoms, although transient, may develop. In moderate to severe cases, and prior to, or in absence of surgical management, the mass, which protrudes from the vulva, must be kept clean and moist and self-mutilation must be prevented. Lubricating jelly, antibiotic and glucocorticoid ointment, artificial tears, protective pants and an Elizabethan collar have been advised for these cases [3,7,8]. However, the edges of an Elizabethan collar can cause further damage to the mucosa [8]. Medical treatment is not advised: a fold prolapse reoccurs frequently, if not treated surgically. Further, treatments with GnRH or hCG to induce premature ovulation have been used with limited success [9]. If premature ovulation takes place, it will provide an advantage of only a couple of days of earlier exposure to the progesterone influence of the luteal phase. Progestagens can have side effects, such as cystic endometrial hyperplasia or endometritis leading to pyometra, especially when administered during an estrogen-dominated phase [10]. In bitches with a vaginal fold prolapse, which extends outside the vulvar lips, amputation is the treatment of choice [8]. A schematic of this treatment is shown in Fig. 2.

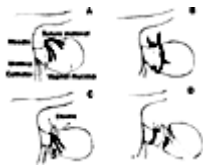


Figure 2. Amputation of a pear-shaped vaginal fold prolapse. A: Needle and two suture strands are transversed through the base of the edematous mucosa, B: Individual sutures are tied, C: Elastic band placed in groove, pulled tight and secured with a suture, D: Redundant vaginal mucosa is amputated [From 8]. - To view this image in full size go to the IVIS website at [www.ivis.org](http://www.ivis.org) . -

The procedure is performed in the non-anaesthetized dog, in general in the standing position, but sometimes positioned in lateral recumbency. Sedation is only used if the bitch is very nervous. The edematous mucosa is exteriorized as much as possible (Fig. 3). A catheter is inserted into the urethra, which is easily seen by lifting the fold prolapse (Fig. 4).



Figure 3. The edematous mucosa of a vaginal fold prolapse in a Doberman, is exteriorized as much as possible. The pen indicates the mucosal fold, which is always present in a pear-shaped vaginal fold prolapse. - To view this image in full size go to the IVIS website at [www.ivis.org](http://www.ivis.org) . -

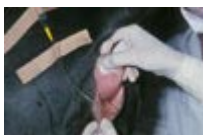

Figure 4. A catheter is inserted into the urethra of a Mastino Napolitano. The urethra is easily seen by lifting the fold prolapse. - To view this image in full size go to the IVIS website at [www.ivis.org](http://www.ivis.org) . -

It is important to keep the anatomy in mind during the entire surgery to prevent damage to the urethra! A large needle threaded with two strands of heavy suture material is inserted and transversed about 1.5 cm distal to the urethral orifice through the base of the fold prolapse (Fig. 5). Individual sutures are tied on both sides of the base of the prolapse (Fig. 6).

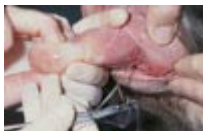

Figure 5. A large needle threaded with two strands of heavy suture material is inserted and transversed about 1.5 cm distal to the urethral orifice through the base of the fold prolapse. - To view this image in full size go to the IVIS website at [www.ivis.org](http://www.ivis.org) . -

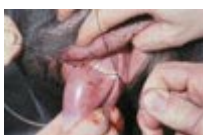

Figure 6. Individual sutures are tied on both sides of the base of the prolapse. - To view this image in full size go to the IVIS website at [www.ivis.org](http://www.ivis.org) . -

Both sutures are brought around the whole prolapse and are securely tied again. An elastic band (Penrose drain) is then placed in the groove created by the sutures and tightened. The elastic band is anchored with suture material to prevent slippage (Fig. 7a and Fig. 7b).

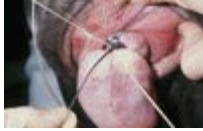

Figure 7a. Both sutures are brought around the whole prolapse and are securely tied again. An elastic band (Penrose drain) is then placed in the groove created by the sutures and tightened. - To view this image in full size go to the IVIS website at [www.ivis.org](http://www.ivis.org) . -

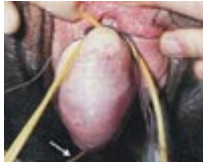

Figure 7b. A second elastic band is then placed, anchored with suture material to prevent slippage. Arrow indicates catheter (b). - To view this image in full size go to the IVIS website at [www.ivis.org](http://www.ivis.org) . -

It is necessary to perform this whole procedure carefully because of the risk of perioperative hemorrhage. The excess suture material and elastic band are cut and the redundant edematous mucosa is amputated (Fig. 8). The remnant stump is replaced in the vagina (Fig. 9). The urethral catheter is removed and the animal is discharged with a plastic collar so that it cannot reach the sutures. The stump distal to the elastic band becomes necrotic and in general the sutures and elastic band will be expelled within a week. To ascertain that this has happened and that there is no foreign material left in the vagina, the bitch should be re-examined a week later.

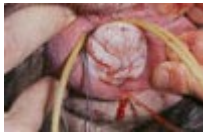

Figure 8. The edematous mucosa has been amputated. The excess suture material and elastic band will be cut. - To view this image in full size go to the IVIS website at [www.ivis.org](http://www.ivis.org) . -

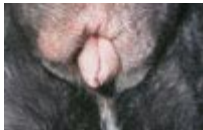

Figure 9. The remnant stump is replaced in the vagina and the urethral catheter is removed. - To view this image in full size go to the IVIS website at [www.ivis.org](http://www.ivis.org) . -

### **Lateral or Circumferential Fold Prolapse**

If the lateral sides or the entire circumference of the vaginal mucosa are involved, the prolapse will have a doughnut shape (Fig. 10). The edematous vaginal tissue is tied off in portions by bringing a needle with two strands of suture material from the center to the outside of the doughnut. Then, one of the loose ends of the suture strands in the center is inserted in a needle along with a new strand and again brought to the outside. This procedure is then repeated until the entire circumference has been covered (Fig. 11).

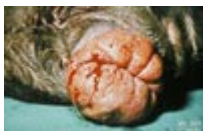

Figure 10. A vaginal fold prolapse involving the entire circumference; the prolapse has a doughnut shape. - To view this image in full size go to the IVIS website at [www.ivis.org](http://www.ivis.org) . -

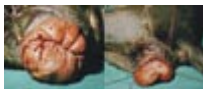

Figure 11. The edematous vaginal tissue is tied off in portions by bringing a needle with two strands of suture material from the center to the outside of the doughnut. Then one of the loose ends of the suture strands in the center is inserted in a needle along with a new strand and again brought to the outside. This procedure is then repeated until the entire circumference has been covered. - To view this image in full size go to the IVIS website at [www.ivis.org](http://www.ivis.org) . -

Each set of two sutures that is brought to the outside is securely tied. This procedure is necessary to assure that all of the prolapsed tissue is tied to prevent hemorrhage. An elastic band is then placed in the groove formed by all the sutures and the prolapse is then amputated as previously described. This procedure results in a closed vagina until the sutures, elastic band and the stump are expelled. It is therefore necessary to perform a vaginal digital exam about one week after the amputation to assure vaginal patency.

### **Prognosis**

Reoccurrence of a vaginal fold prolapse will generally not be seen in subsequent estrous periods if the above-described surgical therapy has been performed. The therapy does not cause constriction of the vagina. Therefore, there is no reason to expect problems during subsequent matings and parturitions. One case of a true vaginal prolapse, in which the bladder was involved, a year after a vaginal fold prolapse was treated as described, has been observed (unpublished observations). The prolapse occurred during parturition.

## **References**

1. McNamara PS. Chronic vaginocervical prolapse with visceral incarceration in a dog. *J Am Anim Hosp Ass* 1997; 33:533-36.
2. Purswell BJ. Vaginal disorders. In: Ettinger SJ, Feldman EC eds. *Textbook of Veterinary Internal Medicine*. Philadelphia: WB Saunders Co, 2000, 1566-1571.
3. Alexander JE, Lennox WJ. Vaginal prolapse in the bitch. *Can Vet J* 1961; 2:428-430.
4. Schutte AP. Vaginal prolapse in the bitch. *J S Afr Vet Assoc* 1967; 38:197-302.
5. Trager CP. Vaginal prolapse in the bitch. *Mod Vet Pract* 1970; 51:39-41.
6. Munnich A, Grussel T, Oelzner J, Walter J. Investigations to the incidence of vaginal diseases in the bitch. *Kleintierpraxis* 1999; 44:831.
7. Jones DE, Joshua JO. Reproductive clinical problems in the dogs. Bristol: PSG Wright, 1982; 22-28.
8. Post K, Van Haaften B and Okkens AC. Vaginal hyperplasia in the bitch: Literature review and commentary. *Can Vet J* 1991; 32:35-37.
9. Rushmer RA. Vaginal hyperplasia and uterine prolapse. In: Kirk R.W. ed. *Current Veterinary Therapy VII, Small Animal Practice*. Philadelphia: WB Saunders Co, 1980; 1222-1224.
10. Schaeffers-Okkens, A.C. Ovaries. In: Rijnberk A. ed. *Clinical Endocrinology of Dogs and Cats*. Dordrecht: Kluwer Academic Publishers, 1996; 131-156.

All rights reserved. This document is available on-line at [www.ivis.org](http://www.ivis.org). Document No. A1210.0401.

